

## Cicatricial Variant of Organizing Pneumonia: A Case Description and Literature Review

Diandra Perez\*, Girish Trikha and Ola El-Zammar

Department of Pathology, SUNY Upstate Medical University, USA

### ARTICLE INFO

Received Date: May 14, 2019

Accepted Date: June 17, 2019

Published Date: June 19, 2019

### KEYWORDS

Cicatricial organizing pneumonia  
Organizing pneumonia  
Cryptogenic organizing pneumonia

**Copyright:** © 2019 Diandra Perez et al., Lung, Pulmonary & Respiratory Research Journal. This is an open access article distributed under the Creative Commons Attribution License, which permits unrestricted use, distribution, and reproduction in any medium, provided the original work is properly cited.

**Citation for this article:** Diandra Perez, Girish Trikha and Ola El-Zammar. Cicatricial Variant of Organizing Pneumonia: A Case Description and Literature Review. Lung, Pulmonary & Respiratory Research Journal. 2019; 2(1):118

### Corresponding author:

Diandra Perez,  
Department of Pathology, SUNY  
Upstate Medical University, USA.  
Email: perezdia@upstate.edu

### ABSTRACT

The cicatricial variant of organizing pneumonia (CCOP) is a distinct morphological manifestation of organizing pneumonia. It may present with shortness of breath, dyspnea on exertion, and dry cough. Imaging is variable, ranging from localized to multifocal disease, and manifesting as ground glass, linear, or reticulonodular infiltrates. Histologically, unlike classical OP, the fibromyxoid plugs of CCOP undergo fibrosis resulting in scar-like nodules and retraction of the surrounding airspace walls, which distorts but does not destroy the underlying architecture. Unlike classical OP, these patients have a variable response to treatment and may even have progressive disease in some cases. Here, we present a case of a 68-year-old male smoker with a history of chondrosarcoma who presented with surveillance CT imaging of the chest concerning for metastasis and was ultimately diagnosed with the cicatricial variant of organizing pneumonia.

### INTRODUCTION

Organizing Pneumonia (OP) was formerly termed bronchiolitis obliterans (BOOP) with organizing pneumonia due to the plugging of bronchiolar airspaces by loose fibromyxoid plugs, however this term was abandoned for the more generally encompassing organizing pneumonia due to the rarity of true BOOP on histological exam. Currently, several variants of OP have been described, all of which may result in varying degrees of response to treatment and overall prognosis.

### CASE PRESENTATION

The patient is a 68-year-old male who presented for evaluation of bilateral pulmonary nodules that were incidentally noted on a surveillance CT scan of the chest that ranged between four and eight mm in maximum dimension (Figure 1). There were no associated respiratory symptoms such as shortness of breath, cough, or hemoptysis and no systemic symptoms such as fever. His past medical history is significant for a Grade 2 chondrosarcoma of the left pelvis for which he underwent left hemipelvectomy six months prior without adjuvant chemo or radiotherapy. Other significant medical history includes a distant history of low-grade renal cell carcinoma status post right partial nephrectomy approximately seven years prior to presentation. He is an ex-smoker with a 30 pack-year smoking history. A follow-up CT scan of chest performed seven months later, revealed enlargement of multiple pulmonary nodules, the largest measuring 12 x 9 mm in the right upper lobe (Figure 2), up from a previous measurement of 8 x 7 mm on the original CT. He underwent percutaneous needle core biopsy of the largest nodule. Microscopic examination

revealed multiple cores of lung parenchyma showing intraalveolar nodules of fibroblasts set in a collagenous and focally myxoid stroma. No associated inflammation was noted.

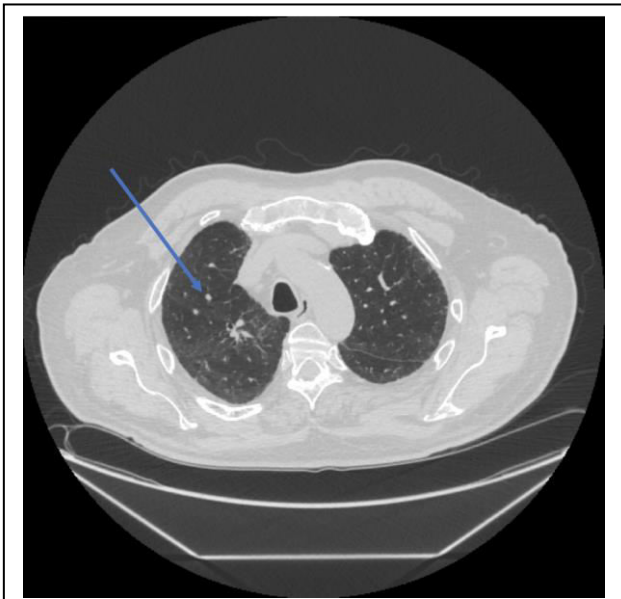


Figure 1: Initial CT image showing the largest nodule measuring 8mm.

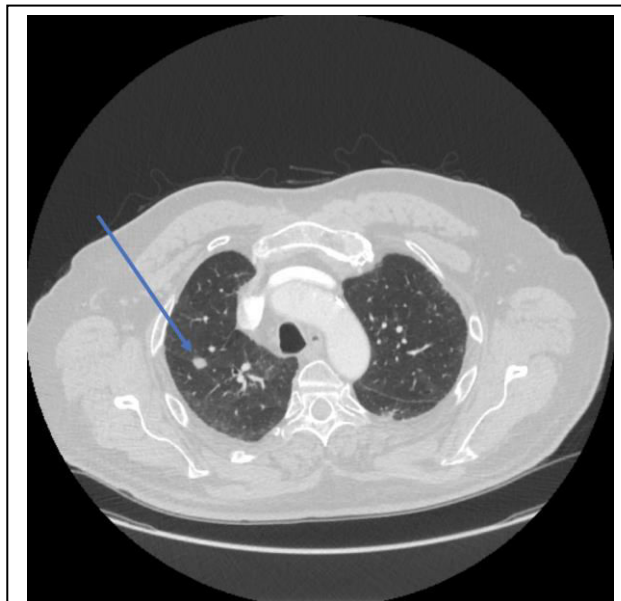


Figure 2: Follow-up CT image showing the largest dimensions measuring 12 mm.

The intervening lung parenchyma showed reactive pneumocyte hyperplasia without evidence of architectural distortion. The findings were consistent with the cicatricial variant of organizing pneumonia (Figure 3 and 4). A follow-up CT scan of the chest performed 6 months later showed an interval decrease in size of the majority of the nodules and a change in appearance from solid to ground glass suggesting resolution.

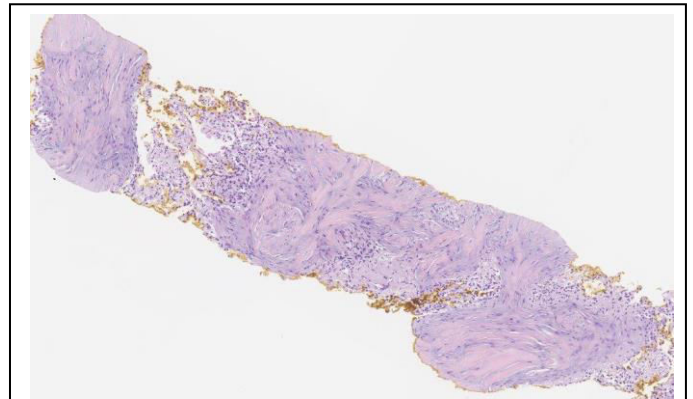


Figure 3: Intermediate magnification showing dense hyalinization and fibrosis.

## DISCUSSION

Organizing Pneumonia (OP), previously referred to as Bronchiolitis Obliterans Organizing Pneumonia (BOOP), is a form of lung injury characterized pathologically by the presence of plugs of fibroblasts filling alveolar ducts and peribronchiolar airspaces, while maintaining the overall pulmonary architecture. The intraluminal plugs are patchy in distribution and are composed of fibroblasts and myofibroblasts arranged in a pale gray matrix and are occasionally admixed with fibrin. A mild interstitial infiltrate of lymphocytes, plasma cells, and histiocytes often accompanies the above findings, most importantly, in the absence of interstitial fibrosis [1]. Symptomatic patients with OP typically have a subacute presentation with cough, dyspnea, fever and flu-like symptoms. Imaging can show a spectrum of findings, which tend to be migratory in nature, including ground glass opacities, solitary nodules, consolidation and diffuse infiltrative opacities [2,3]. Multiple, bilateral, and peripheral alveolar opacities, with a ground glass or consolidated appearance are the most common findings [3,4]. OP can occur as a reaction to a specific injury and potential causes include resolving infections,

drug toxicity, collagen vascular diseases, toxic inhalants, radiation, and aspiration. OP can also occur as a nonspecific reactive change at the edge of other processes such as neoplasms, granulomas, infarcts, etc. [1]. Many cases, however, are idiopathic and fall into the category of Cryptogenic Organizing Pneumonia (COP). The prognosis of COP is generally good, and about 80% of cases respond favorably to corticosteroid therapy with resolution of symptoms and radiographic findings in the majority of cases [1,5]. Ultimately, all etiologies result in the same generally reversible sequence: injury of alveolar epithelium, followed by proliferation and maturation of fibroblasts, and ending with complete resolution [4,5].

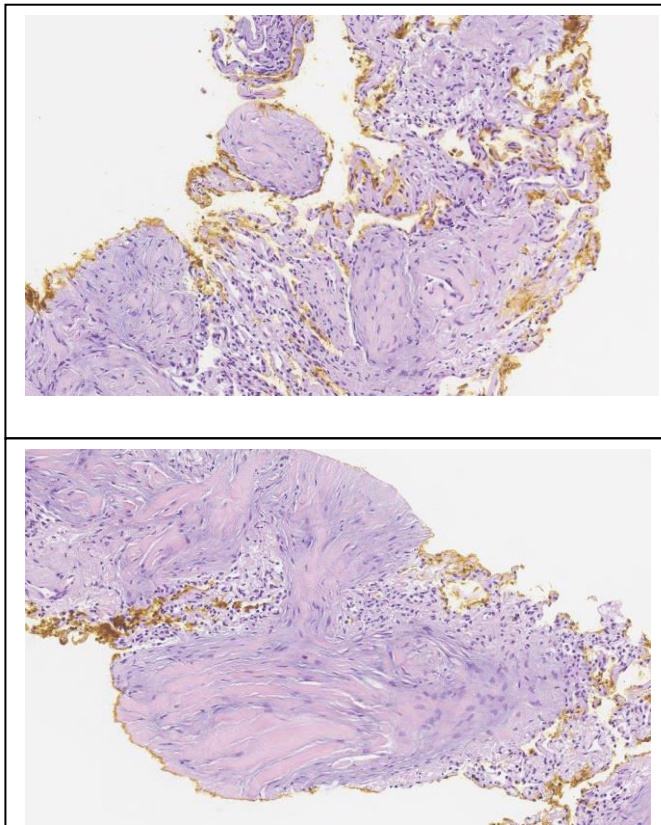


Figure 4a and b: Higher magnification showing fibroblastic nodules and the serpiginous nature of the fibroblastic plugs.

Multiple studies attempted to define predictors of poor outcome in OP. Cases associated with predisposing conditions (secondary OP) such as hematologic disease and collagen vascular disease, or drugs had a worse prognosis compared to patients with idiopathic disease [6-8]. Lohr et al found that

cases of secondary OP were associated with decreased 5-year survival rates and increased respiratory-related deaths [7]. One study described increased frequency of relapses in cases of OP that had delayed onset of treatment or upon discontinuation of treatment and noted that mild cholestasis identified a subgroup of patients prone to multiple relapses, however these relapses did not change overall outcome [9]. Morphologic predictors of prognosis in COP were described in a study comparing steroid-responsive and steroid non-responsive OP by Yousem et al. They noted that there were no significant differences in clinical presentation, demographics, or radiographic findings between the two groups [5]. However, they found that the presence of background remodeling of lung architecture along with dense hyalinization of fibroblast plugs predicted an unfavorable outcome [5]. Those cases with progression had thickened and fibrotic alveolar septa and reduced elastic tissue fibers without evidence of honeycomb change. The changes were especially common in the subpleural zones [5]. Theories about predisposition to scarring in some patients and not in others included chronicity of the lung injury, intensity of the injury, and the presence of underlying lung disease such as emphysema [5]. Some patients with OP/COP progress to a fulminant course with ARDS. Cordier et al described cases in which patients presented with Acute Fibrinous and Organizing Pneumonia (AFOP) where the defining histologic feature is the presence of intraalveolar fibrin (fibrin balls) in the absence of hyaline membranes [4]. In such cases, corticosteroids should be used, but the outcome for some of these patients is unknown. Nishino et al [10] found that patients with increased amounts of intraalveolar fibrin as well as the presence of diffuse infiltrates involving all three lung zones are at increased risk for relapse of their organizing pneumonia and may benefit from more intensive corticosteroid therapy [10]. Special care should be taken in such cases as they may represent OP/COP superimposed on other pathologies.

The term cicatricial variant of COP (CCOP) was introduced by Yousem in 2017 [11]. He described the morphologic findings in 12 patients with COP where, instead of complete resolution, the intraalveolar loose fibromyxoid tissue undergoes progressive fibrosis [11]. Fifty five percent of his cases had progressive or persistent disease. The histology in these

patients was consistent with OP/COP in which the intraalveolar granulation tissue matured to irreversible scar tissue. Elongated fibroblasts projected from the central scar to the alveolar septa, resulting in distortion but not destruction of the underlying architecture. Fibrin was scant or absent. Seventy eight percent presented with localized or multifocal ground glass/alveolar infiltrates, whereas the remaining patients presented with interstitial reticulonodular infiltrates [11]. Fifty eight percent of CCOP cases in that study had significant emphysematous changes suggesting that CCOP arises in lung parenchyma that has been previously damaged. This damage may impair the ability to completely repair and absorb the granulation tissue within the airspaces, which, over time, becomes dense eosinophilic scar tissue, resulting in irreversible fibrosis [11]. Some cases have shown the presence of chronic fibrosing pleuritis, usually associated with infection – these cases may have impaired resolution as well, due to the stiffness of the pleura [11].

**Table 1: Comparison of classical organizing pneumonia and the cicatricial variant of organizing pneumonia.**

Variant	Classical COP	Cicatricial COP
Morphology	Airspace filling by fibroblast plugs and chronic inflammation in a myxoid stroma	Airspace plugs undergo fibrosis and scar formation Fibrotic bands may be seen
Reversible Process?	Yes	No
Findings on Imaging	Variable, but consolidation is most common	Nodular/linear/reticular abnormalities
Treatment and Prognosis	Corticosteroids result in recovery in 85% of cases	Variable Persistence or progressive disease may be seen in up to 55%

Although CCOP does not destroy the lung's architecture, the organizing airspace and airway granulation tissue matures irreversibly into dense eosinophilic scar tissue, creating a nodular infiltration pattern on imaging [11]. Both the histologic and imaging findings may persist in spite of the usual gold standard therapy in contrast with classical OP/COP (Table 1). Cordier et al. also noted poorer prognosis in patients with reticulonodular disease compared to patients with localized infiltrates or alveolar opacities [6]. Churg et al [12] described

10 cases that were thought to have interstitial lung disease due to the presence of linear or reticular abnormalities on CT scans of the chest but on pathologic examination showed the cicatricial variant of OP. Their cases, however, differed morphologically from Yousem's cases [11]. They consisted of fibrotic nodules and bands that pushed the alveolar walls and were invariably accompanied by organizing pneumonia in different stages of organization. They also fared better than the cases described by Yousem [11] in that there was no evidence of progression in cases where radiological follow-up was available.

CCOP should be distinguished from the fibrosing variant of organizing pneumonia [13], which has been described by many but remains ill-defined. Beardsley B, Rasmussen D [13] who proposed the term, suggested that some cases in that category appear to have overlapping features with organizing diffuse alveolar damage. Others may have an underlying fibrotic process, which may have caused the progression, upon which COP is superimposed. However, there are cases with steroid non-responsive OP in which post-mortem examination showed no evidence of underlying fibrotic lung disease such as UIP [5]. Therefore, it appears that in a small proportion of cases, pure OP may be progressive and result in fibrosis and remodelling of the pulmonary architecture and those cases would fit with fibrosing OP. Kobayashi et al defined fibrosing organizing pneumonia to include fibrotic lesions at the alveolar duct level with granulation tissue and adhesions of the alveolar duct walls. The underlying lung architecture was preserved [14].

The morphologic differential diagnosis of cicatricial organizing pneumonia includes the fibroblast foci seen in Usual Interstitial Pneumonia (UIP), especially if they consist of residual loose granulation tissue. CCOP can be distinguished from fibroblast foci, however, by the presence of nearby recognizable classic OP [12]. Cicatricial OP may mimic a fibrosing interstitial pneumonia, especially the fibrosing variant of Nonspecific Interstitial Pneumonia (NSIP) from which it can be separated by the presence of nearby classical OP and by the fact that the process is typically localized. One should keep in mind that OP/COP can be superimposed on either one of these idiopathic interstitial pneumonias and some cases may be difficult to distinguish [4], especially where the alveolar interstitium is expanded by collagen type fibrosis as expected



in NSIP. Focal organizing pneumonia, a subset of OP also described as a nodular variant of organizing pneumonia, should also be considered in patients suspected of having malignancy [2]. It presents as a single nodule on CT and histologically resembles OP. The nodule can resolve with or without treatment.

## CONCLUSION

In summary, we described a case of the cicatricial variant of organizing pneumonia in a 68-year-old asymptomatic male who presented with nodules on surveillance imaging. CCOP varies in its presentation, but most commonly presents with shortness of breath, dyspnea on exertion, and dry cough. Histologically, this variant differs from classical OP in that the airspace fibroblastic plugs undergo fibrosis and scarring. These patients may have a less favorable response to corticosteroid therapy compared to those with classical OP. The imaging of CCOP is just as varied as its presentation, but most commonly presents as nodular, linear, or reticular abnormalities. Multiple differentials may be considered with this clinical presentation and histology, including fibroblast foci of diffuse alveolar damage, fibrosing interstitial pneumonia especially NSIP, fibrosing variant of organizing pneumonia, and focal organizing pneumonia; however, keeping in mind the relatively distinct morphology of CCOP is helpful in arriving at the right diagnosis. A special consideration should be given in the setting of possible metastasis. A small or large nodular infiltrate can be seen in these cases, and one must keep in mind that OP can be a tissue reaction on the edge of a tumor, therefore sampling is critical [3].

## REFERENCES

- Katzenstein AA. (2006). Katzenstein and Askins surgical pathology of non-neoplastic lung disease. Edinburgh: Elsevier Saunders.
- Zhao F, Yan SX, Wang GF, Wang J, Lu PX, et al. (2014). CT features of focal organizing pneumonia: an analysis of consecutive histopathologically confirmed 45 cases. *European Journal of Radiology*. 83:73-78.
- Faria IM, Zanetti G, Barreto MM, Rodrigues RS, Araujo-Neto CA, et al. (2015). Organizing pneumonia: Chest HRCT findings. *J Bras Pneumol*. 41: 231-237.
- Cordier JF. (2006). Cryptogenic organising pneumonia. *European Respiratory Journal*. 28: 422-446.
- Yousem S, Lohr R, Colby T. (1997). Idiopathic bronchiolitis obliterans organizing pneumonia/cryptogenic organizing pneumonia with unfavorable outcome: pathologic predictors. *Modern Pathology*. 10: 864-871.
- Cordier J, Loire R, Brune J. (1989). Idiopathic Bronchiolitis Obliterans Organizing Pneumonia. *Chest*. 96: 999-1004.
- Lohr RH, Bolan BJ, Douglas WW, Dockrell DH, Colby TV, et al. (1997). Organizing Pneumonia Features and Prognosis of Cryptogenic, Secondary, and Focal Variants. *Arch Intern Med*. 157: 1323-1329.
- Cohen AJ, King TE, Downey GP. (1994). Rapidly progressive bronchiolitis obliterans with organizing pneumonia. *American Journal of Respiratory and Critical Care Medicine*. 149: 1670-1675.
- Lazor R, Vandevenne A, Pelletier A, Leclerc P, Court-Fortune I, et al. (2000). Cryptogenic Organizing Pneumonia. Characteristics of Relapses in a Series of 48 Patients. *American Journal of Respiratory and Critical Care Medicine*. 162: 571-577.
- Nishino M, Mathai SK, Schoenfeld D, Digumarthy SR, Kradin RL. (2014). Clinicopathologic features associated with relapse in cryptogenic organizing pneumonia. *Hum Pathol*. 45: 342-351.
- Yousem SA. (2017). Cicatricial variant of cryptogenic organizing pneumonia. *Hum Pathol*. 64: 76-82.
- Churg A, Wright JL, Bilawich A. (2018). Cicatricial organising pneumonia mimicking a fibrosing interstitial pneumonia. *Histopathology*. 72: 846-854.
- Beardsley B, Rassel D. (2013). Fibrosing organizing pneumonia. *J Clin Pathol* 66: 875-881.
- Kobayashi T, Kitaichi M, Tachibana K, Kishimoto Y, Inoue Y, et al. (2017). A Cryptogenic Case of Fulminant Fibrosing Organizing Pneumonia. *Internal Medicine*. 56: 1185-1191.