

Middle Ear Tuberculosis: A Report of Rare Case

Asma Abdullah¹, Azuinlzzati^{1*}, FadzilahIsmail², Nazli Zainuddin² and SittiFarhana Johari²

¹Department of Otorhinolaryngology-Head and Neck Surgery, UniversitiKebangsaan Malaysia, Malaysia

²Department of Otorhinolaryngology, Hospital Sungai Buloh, Malaysia

ARTICLE INFO

Received Date: March 05, 2022

Accepted Date: March 25, 2022

Published Date: March 28, 2022

KEYWORDS

Tuberculosis

Chronic otitis media

Middle ear

Copyright: © 2022 Azuinlzzati Arshad et al., Journal Of Otolaryngology: Research. This is an open access article distributed under the Creative Commons Attribution License, which permits unrestricted use, distribution, and reproduction in any medium, provided the original work is properly cited.

Citation for this article: Asma Abdullah, Azuinlzzati Arshad, FadzilahIsmail, Nazli Zainuddin and SittiFarhana Johari. Middle Ear Tuberculosis: A Report of Rare Case. Journal Of Otolaryngology: Research. 2022; 4(1):133

Corresponding author:

Azuinlzzati Arshad (IzzatiA),
Department of Otorhinolaryngology
Head and Neck Surgery,
UniversitiKebangsaan Malaysia, Kuala
Lumpur Malaysia, JalanYaacob Latif,
Bandar TunRazak, 56000 Cheras,
Wilayah Persekutuan Kuala Lumpur,
Malaysia, Phone: +60126292125;
Fax no :+603-61454222;
Email : azuin85@gmail.com

ABSTRACT

Introduction: The tuberculosis (TB) of the ear is a rare entity. In most cases the presentation resembles that of a chronic otitis media or chronic otitis media with mastoiditis. Irreversible complications such as hearing loss and facial paralysis ensue if the diagnosis is often delayed. In view of its rare incidence, we report a case of middle ear tuberculosis in a 25-year-old male patient.

Objective: The objective of this article is to create an awareness of middle ear tuberculosis, and to consider tuberculosis in the differential diagnosis of chronic otitis media with complications.

Design: Case report

Case presentation: We report a case of middle ear tuberculosis presented in Sungai Buloh Hospital in 2016. He presented with bilateral ear discharge and reduce hearing for 3 months. The HRCT of petrous bone revealed picture of right chronic destructive ear disease and minimal evidence of left chronic otitis media. The diagnosis of middle ear tuberculosis was made on the basis of both histological and microbiological findings.

Conclusion: Middle ear tuberculosis is a rare clinical manifestation of extrapulmonary tuberculosis. The Computed Topography (CT) is the best modality available for the diagnosis of tuberculous mastoiditis. Early administration of anti-tuberculosis drugs dramatically improve the prognosis.

INTRODUCTION

Tuberculosis (TB) is a potentially serious and contagious infectious disease which could affect various organs and tissues. Tuberculosis remains the major cause of death worldwide in individuals older than 5 years secondary to infectious diseases [1]. Tuberculosis otitis media is an uncommon condition. In the early 20th century, tuberculosis otitis media were reported to be 3% to 5% of the cases of chronic suppurative otitis media [2]. Recently, some literature revealed that the incidence of cases of chronic middle ear infection in developed countries is 0.04 % to 0.9% [2,3]. This uncommon presentation of extrapulmonary tuberculosis is apparently underdiagnosed [4]. The incidence is associated with substantial morbidity, and delay in initiating therapy could result in serious complications. These complications include early destruction of the middle ear conductive mechanism, facial paralysis, cochlear involvement with labyrinthitis and sensorineural hearing loss, and intracranial dissemination of infection [3].

CASE REPORT

A 25 year-old male with no known medical illness presented with bilateral ear discharge and reduce hearing for 3 months. He denied trauma to the ear, otalgia, vertigo or tinnitus. There was no complaint of prolong cough or any constitutional symptoms. Past medical and family history was unremarkable with no recent travel or tuberculosis contact. Upon initial examination, pus was noted in both of the ear canals. Aural polyp was also seen inside the left ear canal. The tympanic membrane in both ears were not clearly seen as the ear canals were narrowed. A pure tone audiogram has shown profound hearing lost in both ears.

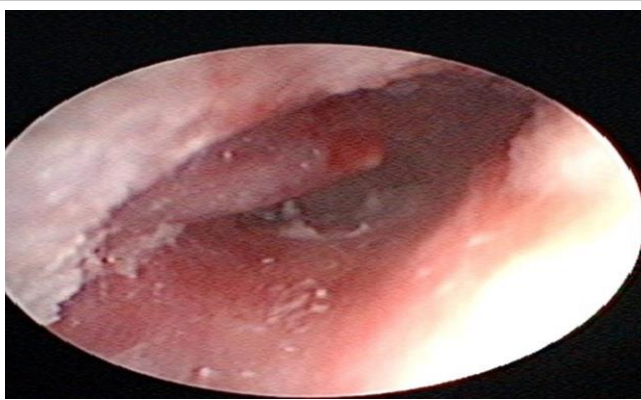

Figure 1 a: Right EAC narrowed with small polyp at EAC (black arrow).

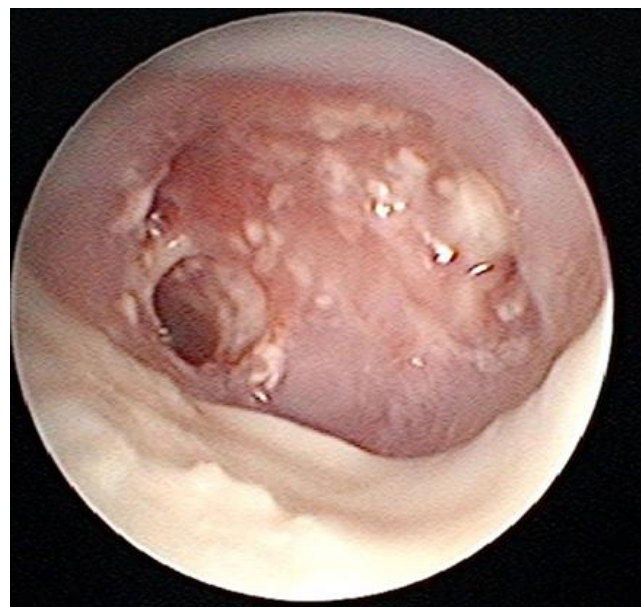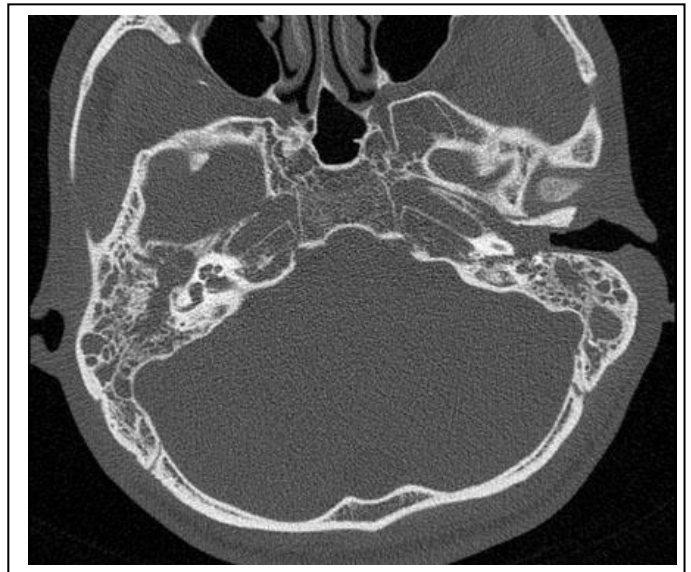


Figure 1 b: Left EAC minimal pus with central tympanic membrane perforation (black arrow).

Patient was initially treated as bilateral suppurative otitis media. He was prescribed a course of oral antibiotics and antibiotic ear drops. Subsequently, during follow up there was no change in the course of disease and High Resolution Computed Tomography (HRCT) of petrous bone was ordered. The HRCT of petrous bone revealed right EAC stenosis with right ossicular erosion, the posterior wall of External Auricular Canal (EAC), tegmen tympani and sigmoid plate dehiscence suggestive of chronic destructive ear disease (Figure 1).

Cholesteatoma was a possible diagnosis. Left temporal bone structures are preserved except for presence of left aural polyp and minimal evidence of chronic otitis media.

Patient was admitted to the ward for a course of intravenous Ciprofloxacin. He subsequently went for examination of ears under general anaesthesia. A biopsy was taken under general anaesthesia from the left aural polyp. The histology study revealed fragmented and inflamed tissue with islands of epitheloid granuloma and scattered multinucleated giant cell of Langhan's type. Some of the cells have central necrosis. ZiehlNeelsen stain showed few acid fast bacilli organism.



With the biopsy result, the patient was further investigated for tuberculosis. Chest X-ray was suggestive of pulmonary tuberculosis changes (Figure 2c). He was later diagnosed with sputum positive tuberculosis. Patient was referred to the infectious disease team and was started on anti-tuberculosis regimen. Upon follow up 6 months into his anti-tuberculosis treatment, he had no more ear discharge however his hearing

has not improved. On otoscopic examination, there was healed central perforation over the right ear. The left ear noted to have retracted tympanic membrane with perforation at anterior superior region.

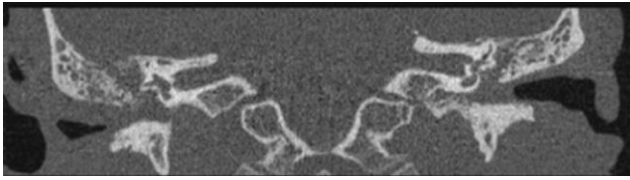


Figure 2b: Axial & Coronal view of HRCT petrous showing bilateral middle ear cavity and mastoid air cells soft tissue density and fluid, right External Ear Canal (EAC) stenosis with erosion of right ossicular chain mastoid air cells, posterior EAC wall, tegmen tympani and sigmoid plate dehiscence. (white arrow)

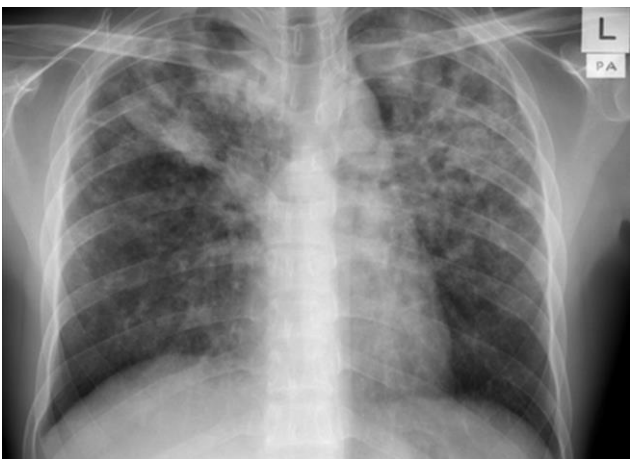

Figure 2c: Anterior and posterior view of chest xray showing bilateral nodular and interstitial opacities more at upper and middle zone consistent with pulmonary tuberculosis changes.

DISCUSSION

Tuberculosis is a chronic bacterial infection caused by *Mycobacterium tuberculosis*. Tuberculosis Otitis Media (TOM) was first reported in 1853, and the organism was first identified in ear discharge in 1883 [5]. TOM is a very infrequent cause of chronic otitis media and is rarely considered in differential diagnosis [6]. The incidence of tuberculosis had been decreasing over the years, due to improvements to the public healthcare services and the availability and efficacy of anti-tuberculosis chemotherapy, but the numbers of cases have increased again over the last few

years mainly because of AIDS, bacillus resistance to antituberculosis therapy, drug dependence, alcohol abuse and diabetes [6]. Although the pathogenesis of TOM is still controversial, three mechanisms explaining middle ear tuberculosis infection have been postulated: aspiration of mucus through the auditory tube, hematogenous transmission from other tuberculosis foci, and direct implantation through the external auditory canal with tympanic membrane perforation [7].

Presentation of tuberculous otitis media could be classical. It should be considered in patients with chronic middle ear infection unresponsive to routine antibiotic therapy with painless ear discharge, hearing loss disproportionate to the extent of disease and multiple perforations, in some cases central or total perforation. The hearing loss can be either conductive (90% of patients), sensorineural (~8%), or mixed (~2%) [4]. Sensorineural hearing loss can be attributed to vasculitis of the cochlear veins, immunocomplex deposits in the cochlea or the presence of granulomatous tissues affecting the acoustic nerve [8]. Facial nerve palsy is rare [9]. Facial nerve palsy associated with tuberculous otitis media is seen in approximately 16% of adult cases and 35% of paediatric cases [10].

Otoscope findings that may mimic cholesteatoma such as the presence of caseous material and granulation tissue which may extend into the mastoid is one of the common tuberculous ear findings [11]. The presence of granulomatous or necrotic aspect, and bony sequestrum usually occur at an advanced stage of the disease. In addition to this, the occurrence of pre-auricular or cervical lymph nodes is not uncommon, and development of retro-auricular fistula is usual [8].

Recent studies have shown that Computed Tomography (CT) is the best modality available for the diagnosis of tuberculous mastoiditis; CT provides more information compared to standard plain films and it is more accurate and useful than polycycloidal tomography and magnetic resonance imaging [12]. Rho et al [13] reported that in most cases, CT scan of temporal bones would reveal soft tissue attenuation in the entire middle ear cavity, preservation of the mastoid air cells without sclerotic change, and soft tissue extension to the External Auditory Canal (EAC) or mucosal thickening of the bony EAC. While others reported that destruction of the

cortical bone was a more frequent finding. This is different from the resorption that begins in Prussak's space, which is characteristic of cholesteatomas [4].

Diagnosis is made from direct smear examination and culture of discharge and histopathological examination from middle ear. High index of suspicion is required even in the absence of pulmonary tuberculosis in diagnosing tuberculous otitis media. Demonstration of AFB (Acid Fast Bacilli) in the ear discharge is difficult. The positivity for AFB in ear discharge varies from 5% to 35% and on repeated examinations it improves to 50% [14]. Histology of tissues reveals granulations with epithelioid cells and multinucleated giant cells (Langhans giant cells), areas of central necrosis, lymphocytic infiltration, ulceration and signs of bone resorption. Histopathological examination of the involved middle ear and mastoid mucosa will show three types of changes: military, granulomatous and caseous. The military type is associated with superficial infection, the granulomatous type with superficial bony involvement, and the caseous type with massive necrosis and sequestration [15].

After diagnosis has been attained, it's crucial to start the medical treatment early to avoid serious complication. In most cases early administration of anti-tuberculosis drugs dramatically improve the prognosis. For complete cure, drug therapy should be taken for at least 6 months. The role of surgery is limited and indications for surgical intervention include cases unresponsive to medical therapy and extensive disease with bone sequestra. However, surgical intervention in the absence of appropriate drug therapy will likely be complicated by fistulae, nonhealing of suture lines, and surgical failure [4,6].

According to Myerson, radical mastoidectomy is indicated if any of the following complications develop: facial paralysis, subperiosteal abscess, labyrinthitis, mastoid tenderness and headache. Surgery may be required in some cases to remove sequestra and improve drainage. When surgery is combined with adequate chemotherapy, there is a good chance of healing with a dry ear with a good prognosis [16]. Recently, the role of surgery has been revised. In the past, it was done to provide drainage, to control spread to central nervous system and to relieve facial paralysis. The advent of specific chemotherapy has challenged all this, and today surgery should be reserved for decompression of the facial nerve and

for removal of necrotic material which might provide a nidus for the organism to remain out of reach of anti tuberculous therapy. Sometimes, demonstration of sequestra in temporal bone during surgery will give a clue to diagnosis [9].

Tuberculous mastoiditis may cause serious complications. When the infection spreads from the ear canal to the nearby tissues such as the skull base or the tegmen tympani, tuberculous mastoiditis could lead to skull base osteomyelitis or tuberculous meningitis [17]. In the past, before the advent of streptomycin many reported mortality were caused by tuberculous otitis media. Now with combined antituberculous therapy, the results improved. However, generally there is no hearing improvement [18]. The recovery of hearing loss can be achieved after cessation of otorrhea by tympanoplasty. In addition, facial paralysis will improve partially or completely. The speed and extent of recovery were directly related to the time interval between the installation of facial paralysis and the start of treatment [19].

CONCLUSION

Middle ear tuberculosis is a rare clinical manifestation of extrapulmonary tuberculosis. The diagnosis is frequently missed and delayed. The CT is the best modality available for the diagnosis of tuberculous mastoiditis. Early administration of anti-tuberculosis drugs dramatically improve the prognosis. Surgery may be required in to provide samples for bacteriological and histological study. In some cases surgery aims to remove sequestra and improve drainage.

REFERENCES

1. Chyo YS, Lee HS, Kim SW, Kyu-Hwan Chung, Dong-Kyung Lee, et al. (2006). Tuberculous otitis media: A clinical and radiological analysis of 52 patients. *Laryngoscope*. 116: 921-927.
2. Pedro Vaamonde, Crisanto Castro, Nicolas García-Soto, Torcuato Labella, Ascensión Lozano. (2004). Tuberculosis Otitis Media: A Significant Diagnostic Challenge. *Head Neck Surg*. 130: 759-766.
3. Ma KH, Tang PSO, Chan KW. (1990). Aural Tuberculosis. *Am J Otol*. 11: 174-177.
4. Farrugia EJ, Ali Raza S, Phillipps JJ. (1997). Clinical Records Tuberculous Otitis Media - A Case Report. *J Laryngol Otol*. 111: 58-59

5. Awan MS, Salahuddin I. (2002). Tuberculous otitis media: two case reports and literature review. *Ear Nose Throat J.* 81: 792-794.
6. Chirch LM, Ahmad K, Spinner W, Jimenez VE, Donelan SV, et al. (2005). Tuberculous otitis media: report of 2 cases on Long Island, N.Y., and a review of all cases reported in the United States from 1990 through 2003. *Ear Nose Throat J.* 84: 488-492.
7. Sens PM, Almeida CI, Valle LO, Costa LH, Angeli ML. (2008). Tuberculosis of the ear, a professional disease? *Braz J Otorhinolaryngol.* 74: 621-627.
8. Bhalla RK, Jones TM, Rothburn MM, Swift AC. (2001). Tuberculous Otitis Media- A Diagnostic Dilemma. *AurisNasus Larynx.* 28: 241-243.
9. Kim CW, Jin JW, Rho YS. (2007). Tuberculous otitis media developing as a complication of tympanostomy tube insertion. *Eur Arch Otorhinolaryngol.* 264: 227-230.
10. Hadfield PJ, Shah BK, Glover GW. (1995). Facial palsy due to tuberculosis: the value of CT. *J LaryngolOtol.* 109: 1010-1012.
11. SkolnikPR, Nadol JB Jr, Baker AS. (1986). Tuberculosis of the middle ear: review of the literature with an instructive case report. *Rev Infect Dis.* 8: 403-410.
12. Hoshino T, Miyashita H, Asai Y. (1994). Computed tomography of the temporal bone in tuberculous otitis media. *J LaryngolOtol.* 108: 702-705.
13. Rho MH, Kim DW, Kim SS, Sung SY, Kwon JS, et al. (2007). Tuberculosis otomastoiditis on high-resolution temporal bone CT: comparison with nontuberculous otomastoiditis with and without cholesteatoma. *Am J Neuroradiol.* 28: 493-496.
14. Manju M, Agarwal DS, Singh NP, Gadre DJ, Manju Mahajan. (1995). Tuberculosis of the middle ear-a case report. *Ind J Tub.* 42: 55-56.
15. WindleTaylor, PC Bailey CM. (1980). Tuberculosis otitis media- A Series of 22 Patients. *Laryngoscope.* 90: 1039-1044.
16. Myerson MC, Gilbert JG. (1941). Tuberculosis of the middle ear and mastoid. *Arch Otolaryngol.* 33: 231-250.
17. Duclos JY, Darrouzet V, Ballester M, Bebear JP, Bebear CM. (1999). Tuberculose de l'oreille moyenne ; *Encycl Med Chir (Elsevier,Paris), Otorhino-laryngologie.* 20-235-A-10.
18. Mills RP. Management of chronic suppurative otitis media. In: Kerr AG, Booth JB eds. *Scott- Brown's.*
19. Wallner LJ. (1953). Tuberculous otitis media. *Laryngoscope.* 63: 1058-1077.