

A Surgical Case Report: Scaphoid Bony Irregularity Leading to Tendon Entrapment and Attrition

George M. Weisz*, Peter Scougall and Michael Houang

University of New South Wales and University of New England, Australia

ARTICLE INFO

Received Date: July 21, 2022

Accepted Date: July 27, 2022

Published Date: July 29, 2022

KEYWORDS

Flexor carpi-radialis
Scapho-trapezoid trapezoid
Tendinopathy

Copyright: © 2022 George M. Weisz et al. Annals Of Orthopaedics, Trauma And Rehabilitation. This is an open access article distributed under the Creative Commons Attribution License, which permits unrestricted use, distribution, and reproduction in any medium, provided the original work is properly cited.

Citation for this article: George M. Weisz, Peter Scougall and Michael Houang. A Surgical Case Report: Scaphoid Bony Irregularity Leading to Tendon Entrapment and Attrition. Annals Of Orthopaedics, Trauma And Rehabilitation. 2022; 5(1):142

Corresponding author:

George M. Weisz
University of New South Wales,
Sydney, and University of New
England, Armidale, Australia,
Email: gmweisz1@aol.com

ABSTRACT

The complex bony structure of the wrist and associated soft tissue attachments allows a unique combination of mobility and strength, but also renders the wrist vulnerable to injury. The scaphoid is the most commonly injured carpal bone, accounting for more than 80% of carpal fractures. Scaphoid fractures and their sequelae are frequently discussed in hand surgery literature. Flexor Carpi-Radialis (FCR) tendinitis is unusual as an isolated diagnosis and is more commonly related to adjacent pathology. The most frequent cause is Scapho-Trapezoid Trapezoid (STT) osteoarthritis and an associated volar capsule tear, causing STT spurs to irritate the overlying FCR tendon. We report a case of FCR tendinopathy (tendon attrition and inflammation) from traumatic scaphoid tubercle irregularity, without STT arthritis.

CASE REPORT

A 55-year-old man, in good general health, with dominant right hand experienced a low-grade discomfort for some months, aggravated by a fall on an extended wrist. Symptoms were of discomfort and restrictions in mobility. Proper clinical assessment was delayed for some two years, until a hand surgeon (author no.2, PS) was consulted. The clinical diagnosis was of flexor carpi radialis tendinitis. The diagnosis was confirmed in plain x-ray detecting a rather prominent tubercle of the scaphoid bone (Figure 1) and further diagnosed by an MRI scan, namely narrowed canal for the tendon between an enlarged scaphoid tubercle, and a rough trapezoid ridge, tethering the flexor tendon next to the prominent bony scaphoid tubercle [1,2].

Radiology: “Plain X-rays showed scaphoid tubercle prominence and irregularity.” (Figure 1) and the MRI study showed scaphoid tubercle irregularity, FCR tendinopathy and a tight FCR tunnel extending beneath the trapezoid ridge (Figure 2,3a,3b). Also seen on MRI slices was “marbling” of the FCR tendon, consistent with tendinopathy (Figure 4).

Surgical exploration: detected 40% FCR attrition and sheath adhesions, which were debrided. The rough scaphoid tubercle and volar STT surfaces were debrided to smooth bone. STT articular cartilage was otherwise healthy (no arthritis). The trapezoid ridge was resected and the FCR sheath floor augmented with an ulnar based sheath flap, to protect the tendon from further injury.

Follow up was unremarkable and the patient reported good functional recovery.

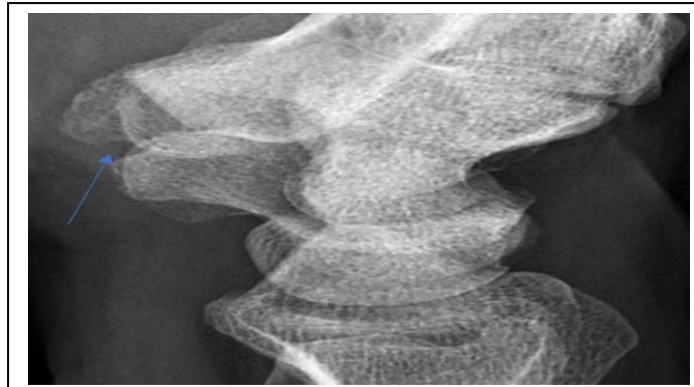


Figure 1: Lateral wrist plane x-ray with prominent scaphoid tubercle (Blue arrow), otherwise unremarkable.

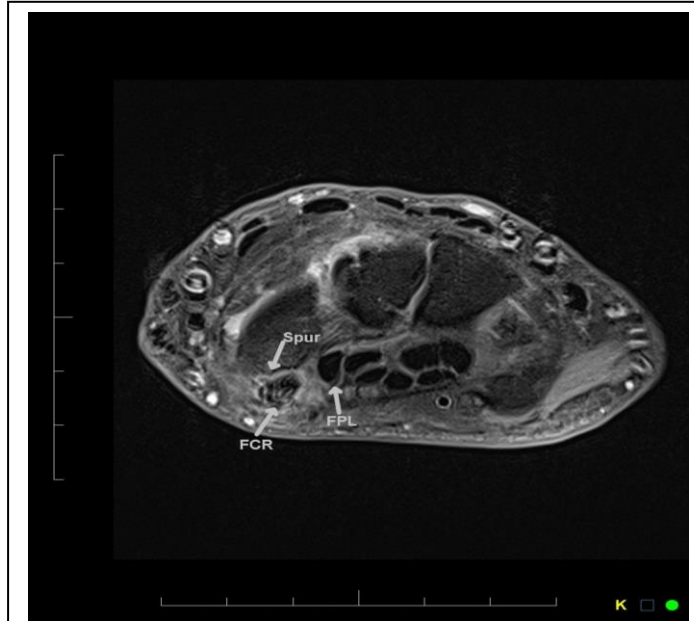

Figure 2: MRI image (Proton Dense with fat saturation) of wrist, at the level of scaphoid spur before diving deep to 2nd metacarpal insertion, FCR is grossly thickened with multiple interstitial high signals (“marbelling effect”) and peritendon oedema, suggesting tendinitis with intra substance tears.(compare with normal black FPL, flexor pollicis longus tendon).

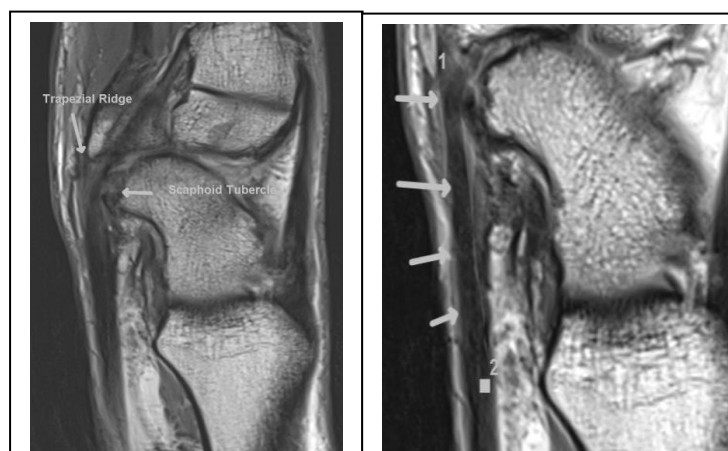


Figure 3b: MRI Sagittal Proton Dense showing large scaphoid tubercle, (spur-like) with compression of FCR (arrowed) as it dives under the thickened trapezoidal ridge.

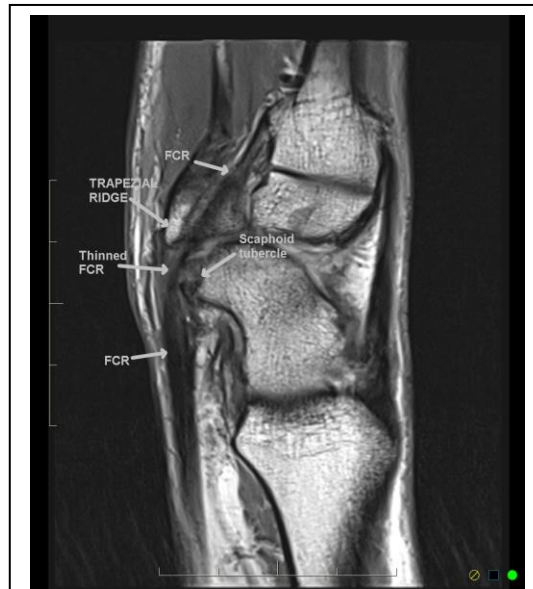

Figure 4: MRI (Proton Dense Sagittal) scaphoid spur with tendinopathy and tear of FCR in the segment arching over the scaphoid tubercle (Spur) diving under an irregular trapezial ridge, prior to insertion at the 2nd metacarpal base.

DISCUSSION

A minor pathology, with prolonged moderate symptomatology, the patient was a victim of restricted Health Service during the Covid pandemic. The pathology is well known when friction of tendon to the prominent scaphoid tubercle leads to attrition of fibres (40%) within the tendon [3,4]. A clearing of the "tunnel" left enough tendon tissue for flexion function, and decompression allowed for an asymptomatic condition. The patient remained free of symptoms for 1,5 years to come.

REFERENCES

1. Plancher KD. (2017). Flexor Carpi Radialis Tunnel syndrome. Images in Orthopaedic.
2. Bodor D. (2018). Flexor Carpi Radialis Tendinopathy. MRI Web Clinic.
3. Duncan SFM, McCormack RR, Roberts CC. (2006). Characteristics of the Flexor Carpi Radialis Brevis Tendon on Magnetic Resonance Imaging. Radiol Case Rep. 1: 24-26.
4. Stoop N, Bonheur ATD, Janssen SJ, Kuntz MT, David Ring, et al. (2019). Incidental Flexor Carpi Radialis Tendinopathy on Magnetic Resonance Imaging. Hand NY. 14: 632-635.