

Arthroscopic Management of an Intraosseous Ganglion Cyst in the Proximal Tibia

Atul Bandi^{1*}, Raghavan Sivaram², Rahul Bagul³ and Hesham Al Khateeb⁴

Department of Orthopedics, India

ARTICLE INFO

Received Date: February 04, 2022

Accepted Date: February 22, 2022

Published Date: February 24, 2022

KEYWORDS

Intraosseous ganglion

Proximal tibia

Arthroscopy

Cyst

Copyright: © 2022 Atul Bandi et al., Annals Of Orthopaedics, Trauma And Rehabilitation. This is an open access article distributed under the Creative Commons Attribution License, which permits unrestricted use, distribution, and reproduction in any medium, provided the original work is properly cited.

Citation for this article: Atul Bandi, Raghavan Sivaram, Rahul Bagul and Hesham Al Khateeb. Arthroscopic Management of an Intraosseous Ganglion Cyst in the Proximal Tibia. Annals Of Orthopaedics, Trauma And Rehabilitation. 2022; 4(1):133

Corresponding author:

Atul Bandi,

Department of Orthopedics, India

Email: atulbandi@gmail.com

ABSTRACT

We report a case of an intraosseous ganglion in the upper end of the tibia which was managed arthroscopically. A sixty-five years old gentleman presented with left sided knee pain, plain radiographs demonstrated a small well circumscribed radiolucent lesion with thin sclerotic margins in the subchondral region of the proximal tibia. An MRI examination revealed the lesion measuring 1x1 centimetre in diameter and was noted to extend in to the articular surface. The patient underwent an arthroscopy of the knee, and this revealed a cystic lesion containing yellowish-brown mucinous fluid, not involving the anterior cruciate ligament; however, it appeared as a prominence with cartilage thinning, just medial to the tibial footprint of anterior cruciate ligament. The cyst was arthroscopically curetted. Further histological examination of the cyst wall and the thick mucoid material confirmed the diagnosis of an intraosseous ganglion. At one year follow-up, the patient was pain free and was able to return to normal daily activities without any restrictions.

INTRODUCTION

Soft tissue ganglia are commonly found benign tumors mainly in the extremities and sporadically show signs of bony erosions; however, intraosseous ganglia are rare [1-4]. These lesions are commonly seen in the lower extremity, proximal tibia and hip joints being the most common sites [2,5,6]. There are also few reports in the literature regarding intraosseous ganglia around the ankle. Most of these lesions were involving tarsal bones and distal tibia [3,5,7-9]. Few reports on lesions in the upper end of the humerus [10-12] and proximal tibia [13] have also been published. These are lesions which contain a thick mucinous material, without any synovial lining and are predominantly found in the fourth or fifth decades of life. Furthermore, these are always found in the periarticular area and almost never seen in children.

CASE PRESENTATION

A sixty five year old man presented with six months duration of knee pain. He did not give any previous history of injury and was treated conservatively with analgesics and physical therapy in the past. The physical examination revealed terminal restriction of flexion beyond 110°, no extensor lag along with a mild supra-patellar effusion and localized tenderness in the upper end of the tibia, in close proximity to the medial edge of the patella tendon. Clinically, the menisci, collaterals and the cruciate ligaments were normal. Plain radiographs of the left knee joint demonstrated

a small well circumscribed radiolucency with thin sclerotic margins involving the subchondral region of the upper end of the tibia with grade 2 osteoarthritic changes (Figure 1 (a),(b)).

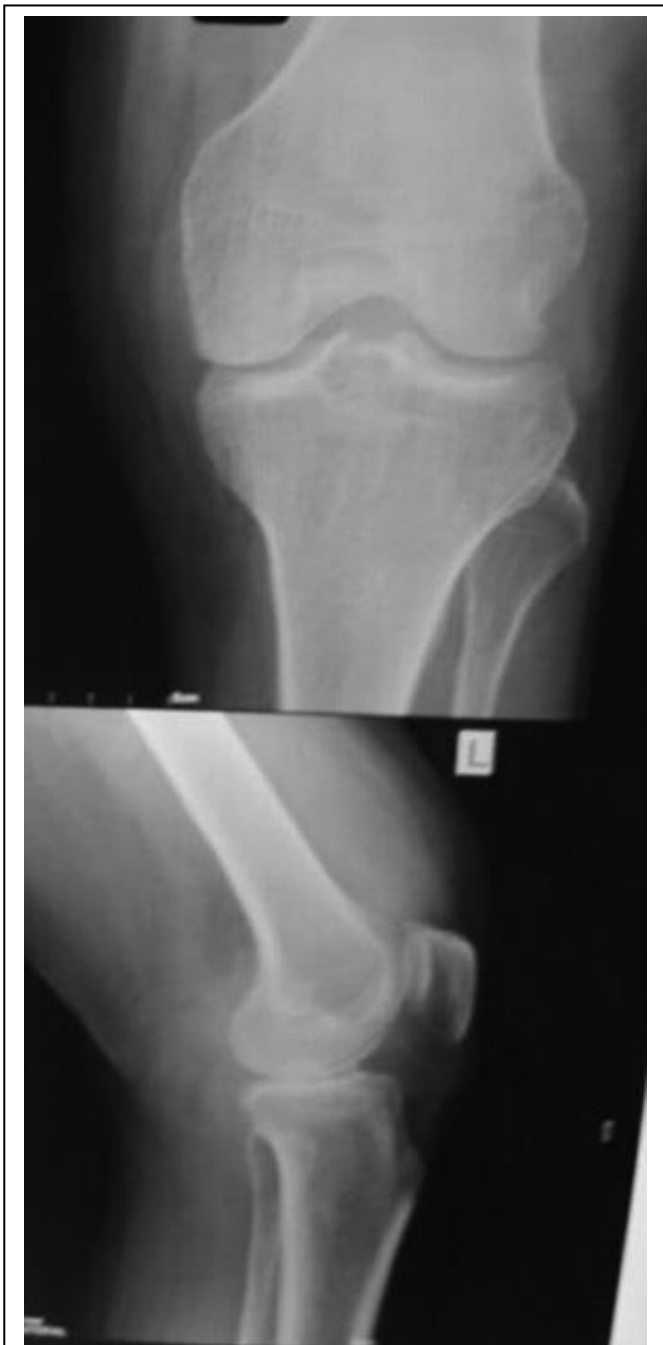

Figure 1: X ray of the knee joint showing juxta articular intraosseous cyst (a) AP view, (b) Lateral view.

Furthermore, the inflammatory markers were within normal range. The patient underwent a magnetic resonance scan to confirm the diagnosis, which revealed fluid signal in the described lesion with low signal intensity on T1-weighted

images and high signal intensity on T2-weighted images (Figure 2 (a),(b) and Figure 3(a),(b)).

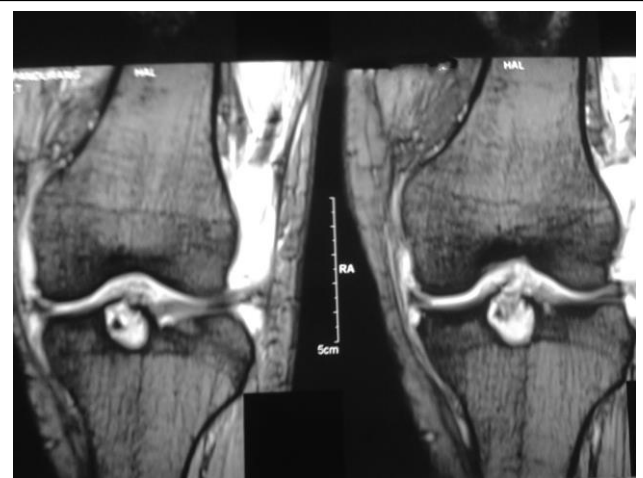


Figure 2: MRI of the knee joint T1 Image (a) and (b) showing intraosseous cyst.

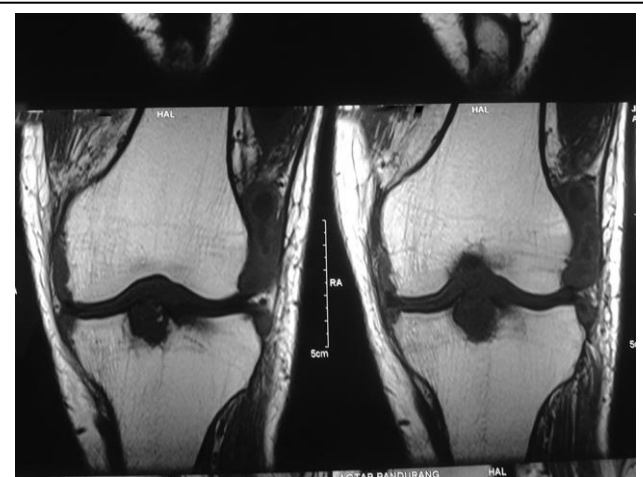


Figure 3: MRI of the knee joint T2 Image (a) and (b) showing periarticular intraosseous cyst.

The diagnosis was narrowed down to an osteochondritis dissecans, chondroblastoma, chondromyxoid fibroma, giant cell tumor, fibrous dysplasia, a subchondral cyst and an intraosseous ganglion. We decided to perform an arthroscopy after the MRI, since the condition was extremely painful. Under spinal anaesthesia, using standard anterolateral and anteromedial portals, the knee joint was examined. Intraoperatively, we were able to visualize mild osteoarthritic changes in the medial and lateral compartments, as well as identify the prominence of the ganglion cyst over articular surface just medial to the tibial footprint of the anterior cruciate ligament and just

posterior to the anterior horn of medial meniscus (Figure 4). However, both the cruciate ligaments were found to have good tension on probing. We performed a thorough debridement of the cartilage fibrillation and de-bulked the fibrous tissue overlying the articular prominence using a Stryker 3.5 millimeters aggressive shaver blade. Using an arthroscopic burr, the superior surface of the cyst, adjoining the tibial eminence was gradually visualized and the location was confirmed in both AP and lateral views by image intensifier. The inferior, medial and lateral walls of the lesion were well defined and were approximately 1 x 1 centimeter in diameter.

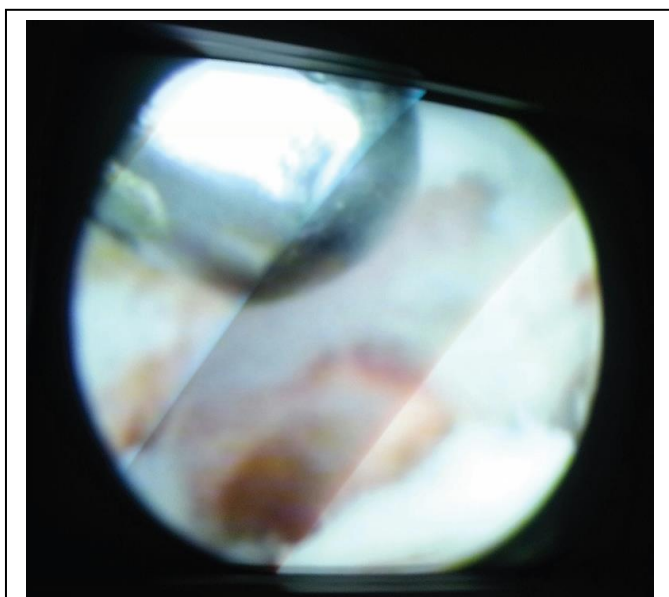


Figure 4: Arthroscopic image of intraosseous cyst near tibial footprint of anterior cruciate ligament.

The lesion was found to be cystic containing yellowish-brown mucinous and gelatinous material. The cyst walls were thoroughly curette using a small angulated bone curette and the overlying cartilage remnants were also removed. Bone grafting was not undertaken as the lesion was insignificant in size. The walls of the cyst and the overlying cartilage were sent for histopathological examination. The cyst did not appear to involve the anterior cruciate ligament or weaken its integrity. Histologically, the cyst was lined by dense fibrous tissue with spotty areas of calcification without a continuous synovial layer confirming the diagnosis of a ganglion. In the immediate post-operative period, the patient was started on weight bearing as tolerated on the first day and was put on physical therapy with

emphasis on quadriceps strengthening. In one year, he was pain-free and was carrying out his routine daily activities.

DISCUSSION

Intraosseous ganglia are rare, benign lesions of the bone with histological similarity to that of soft tissue [1,14,15]. Various terms such as subchondral bone cyst, synovial bone cyst, intraosseous mucoid cyst, or juxta-articular bone cyst have been proposed. The exact aetiology of the intraosseous ganglion remains unknown but various theories have been postulated [13,16,17]. Plain radiographs, most often than not demonstrates these lesions, and further imaging studies such as MRI scans are needed to exclude other possible differential diagnosis. Helwig et al., [5] reported on forty cases with the medial malleolus being predominantly involved and mainly treated by curettage with bone grafting. Schajowicz et al., reported 88 cases of the past 17 years with follow ups from 1 to 12 years which were managed with an open excision of the ganglion and bone grafting, or curettage, only four recurrences were reported [17]. Alexandre Cerlier Jr reported on four cases of intraosseous ganglions involving the lunate bone operated arthroscopically with bone grafting and reported good results and no recurrences with the main advantages being reduced joint stiffness, scarring and preservation of vital structures [18]. Recently, Mc Crum et al reported on a novel arthroscopic technique used in the treatment of an intraosseous ganglion cyst involving the proximal humerus with an additional advantage of being able to identify and treat other glenohumeral joint pathologies [10]. Lorenz Buchler reported on an arthroscopically assisted technique for removal of intraosseous ganglion cysts involving the distal tibia without any recurrences [19]. We explored the possibility of achieving adequate marginal excision of intraosseous ganglion cysts of the upper end of the tibia by an arthroscopically assisted technique to avoid an open procedure and its associated morbidity such as joint scarring and stiffness. We found it prudent to report this case since there are only few published reports on intraosseous ganglions involving the upper end of the tibia and furthermore, to our knowledge, no reports on arthroscopically managed intraosseous ganglion cysts involving the proximal tibia.

CONCLUSION

This report will help throw light on the possibility of an arthroscopic excision of such intra-osseous ganglia cystic lesions and also enlighten orthopedic surgeons about how these cysts are different from the intra-articular ganglion cysts involving the cruciate ligaments. In conclusion, we feel that an arthroscopic management of an intra-osseous cyst improves patient satisfaction and compliance since it is a less invasive modality of treatment with earlier return to full weight bearing and normal activities. Further follow up of the patient with serial plain radiographs is needed not only to rule out recurrence but also to assess any articular surface collapse.

REFERENCES

- Feldman F, Johnston A. (1973). Intraosseous ganglion. *Am J Roentgenol Radium Ther Nucl Med.* 118: 328-343.
- Ferkel RD, Field J, Scherer WP, Bernstein ML, Kasimian D. (1999). Intraosseous ganglion cysts of the ankle: a report of three cases with long-term follow-up. *Foot Ankle Int.* 20: 384-388.
- Murff R, Ashry HR. (1994). Intraosseous ganglia of the foot. *J Foot Ankle Surg.* 33: 396-401.
- Pope TL Jr, Fechner RE, Keats TE. (1989). Intra-osseous ganglion: report of four cases and review of the literature. *Skeletal Radiol.* 18: 185-187.
- Helwig U, Lang S, Baczynski M, Windhager R. (1994). The intraosseous ganglion: a clinical-pathological report on 42 cases. *Arch Orthop Trauma Surg.* 114: 14-17.
- Williams HJ, Davies AM, Allen G, Evans N, Mangham DC. (2004). Imaging features of intraosseous ganglia: a report of 45 cases. *Eur Radiol.* 14: 1761-1769.
- Rozbruch SR, Chang V, Bohne WH, Deland JT. (1998). Ganglion cysts of the lower extremity: an analysis of 54 cases and review of the literature. *Orthopedics.* 21: 141-148.
- Scholten PE, Altena MC, Krips R, van Dijk CN. (2003). Treatment of a large intraosseous talar ganglion by means of hindfoot endoscopy. *Arthroscopy.* 19: 96-100.
- Mohapatra A, Patel V, Choudhury P, Phalak M. (2018). Intraosseous ganglion cyst of the distal tibia: a rare entity in a rarer location. *BMJ Case Rep.* 2018: bcr-2018-224395.
- McCrum CL, Yi A, Omid R. (2015). Arthroscopic Decompression and Bone Grafting of Proximal Humeral Intraosseous Ganglion: A Novel Technique. *Techniques in Shoulder & Elbow Surgery.* 16: 29-31.
- Muir B, Kissel JA, Yedon DF. (2011). Intraosseous ganglion cyst of the humeral head in a competitive flat water paddler: case report. *J Can Chiropr Assoc.* 55: 294-301.
- Karabulut YY, Dolek Y, Ganai I. (2014). Ganglion cyst of the proximal humerus: A case report and review of the literature. *J NTR Univ Health Sci.* 3: 45-47
- Jamshidi Kh, Bagherifard A, Yahyazadeh H. (2013). Intraosseous ganglion of the medial condyle of the tibia: a case series of 7 patients. *Shafa Ortho J.* 1: 17-21.
- FISK GR. (1949). Bone concavity caused by a ganglion. *J Bone Joint Surg Br.* 31: 220-221.
- Crabbe WA. (1966). Intra-osseous ganglia of bone. *Br J Surg.* 53: 15-17.
- Kambolis C, Bullough PG, Jaffe HI. (1973). Ganglionic cystic defects of bone. *J Bone Joint Surg Am.* 55: 496-505.
- Schajowicz F, Clavel Sainz M, Stullitel JA. (1979). Juxta-articular bone cysts (intra-osseous ganglia): a clinicopathological study of eightyeight cases. *J Bone Joint Surg Br.* 61: 107-116.
- Cerlier A Jr, Gay AM, Levadoux M. (2015). Arthroscopic Treatment of Intraosseous Ganglion Cyst of the Lunate Bone. *Arthrosc Tech.* 4: 513-518.
- Buchler L, Hosalkar H, Weber M. (2009). Arthroscopically assisted removal of intraosseous ganglion cysts of the distal tibia. *Clin Orthop Relat Res.* 467: 2925-2931.