

# Combined Transcranial Magnetic Stimulation and Ketamine for Treatment of Suicidal Ideation, Refractory Mood Disorder, Neurotoxicity and Pain: a Case Report

Steve Besta<sup>1\*</sup> and Dan G. Pavelb<sup>2</sup>

<sup>1</sup>The Neuroscience Center, USA

<sup>2</sup>Path Finder Brain SPECT Imaging, USA

## ARTICLE INFO

Received Date: September 29, 2017

Accepted Date: October 30, 2017

Published Date: November 09, 2017

## KEYWORDS

Ketamine;  
Transcranial magnetic stimulation;  
Depression;  
Suicidal ideation;  
Pain;  
Neurotoxicity;  
Brain SPECT;  
Functional imaging

**Copyright:** © 2017 Besta S et al., Anxiety Depress J This is an open access article distributed under the Creative Commons Attribution License, which permits unrestricted use, distribution, and reproduction in any medium, provided the original work is properly cited.

**Citation this article:** Besta S, Pavel DG. Combined Transcranial Magnetic Stimulation and Ketamine for Treatment of Suicidal Ideation, Refractory Mood Disorder, Neurotoxicity and Pain: a Case Report. Anxiety Depress J. 2017; 1(1):112.

## Corresponding Author :

Steve Besta, The Neuroscience Center, 440 Lake Cook Road, Bldg 2, Deerfield, IL 60015, USA,

**Tel:** 847 236-9310;

**Fax:** 847 236-9411;

**Email:** srbest@neuroscience.md

## ABSTRACT

Treatment Resistant Depression (TRD) is a major public health problem, with approximately one third of patients failing to respond to multiple antidepressant medications. It can be associated with suicidal ideation. When it occurs alongside chronic pain and neurotoxicity (substance misuse/abuse whether iatrogenic or illicit) it is especially likely to be resistant to treatment. A factor underlying TRD is dysregulation of a thalamo-cortical circuit including the anterior cingulate cortex. Recent research has shown the efficacy of transcranial magnetic stimulation, and of intravenous ketamine, as therapeutic approaches in treatment resistant depression and anxiety. We hypothesized that stimulating the ACC with TMS would facilitate entrainment of this circuit, thereby improving response to ketamine. We describe the combination therapy of Transcranial Magnetic Stimulation (TMS) and ketamine for an adult female patient with severe, long-term depression, with recent suicidal ideation triggered by death of her spouse, all comorbid with chronic pain and iatrogenic neurotoxicity. Pre- and post-treatment assessments indicated that this approach resulted in substantial symptom reductions in all disorders. This was corroborated by the significant functional improvement seen at follow-up on brain imaging with Single Photon Emission Computed Tomography (SPECT).

## ABBREVIATIONS

ACC: Anterior Cingulate Cortex; BPI-SF: Brief Pain Inventory-Short Form; Ceretec: 99mTechnetium-HMPAO; HMPAO: hexamethylpropyleneamineoxime; NMDA: N-Methyl-D-Aspartate; OASIS: Overall Anxiety Severity; Imap; PHQ-9: Patient Health Questionnaire; SPECT: Single Photon Emission Computed Tomography; TRD: Treatment Resistant Depression; TMS: Transcranial Magnetic Stimulation

## INTRODUCTION

Treatment Resistant Depression (TRD) is a major public health problem, with approximately one third of patients failing to respond to multiple antidepressant medications [1]. In addition, TRD is associated with general medical costs estimated to be approximately 20 times greater than those stemming from depression that is responsive to treatment [2]. Depression occurring alongside a comorbid anxiety disorder and/or pain may contribute to treatment resistance [1-3]. To address these challenges, recent research has investigated the efficacy of Transcranial Magnetic Stimulation (TMS) and its variant (r) TMS as a treatment for TRD and anxiety [4,5]. Most studies have used TMS to apply electromagnetic stimulation to the dorsolateral prefrontal cortex, a region implicated in both depression and anxiety [6-8]. Unfortunately, few studies have demonstrated full remission with TMS alone. A parallel body of research suggests a positive effect of ketamine, an N-Methyl-D-Aspartate (NMDA) antagonist, on both depression [9] and pain [10,19]. A primary benefit of ketamine is that it provides rapid albeit short-term relief from TRD symptoms relating to suicidality within approximately two hours. To date, little is known about the possible synergistic effects of combined TMS/ketamine for TRD alone, or comorbid with pain.

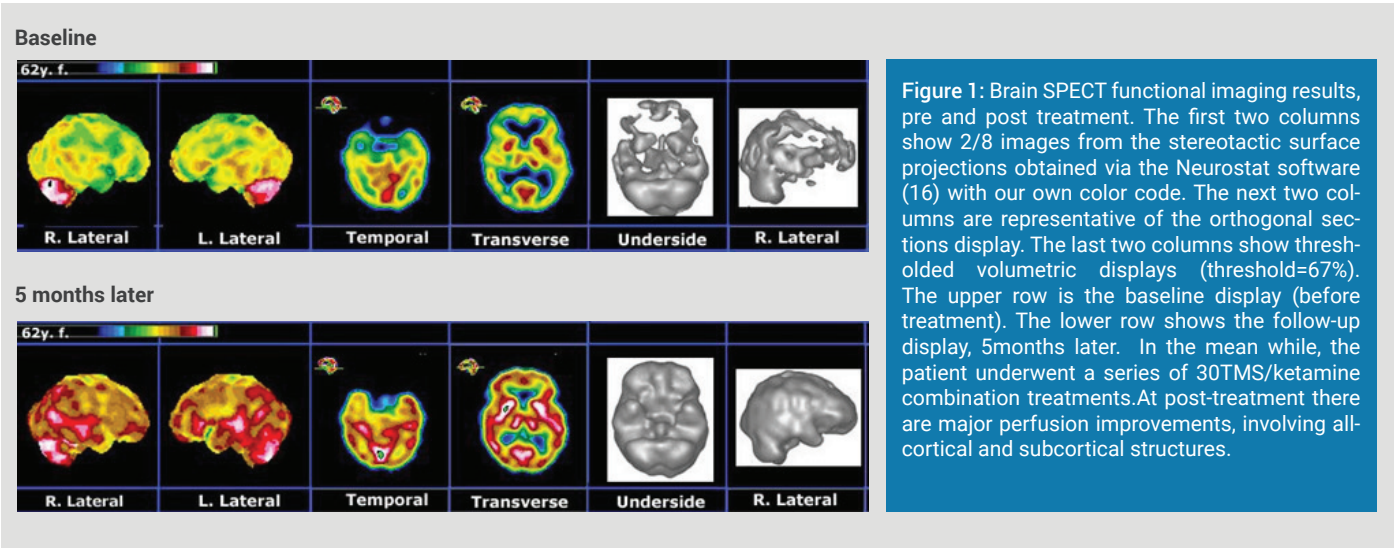
Research suggests that a factor involved in TRD is dysregulation of a thalamo-cortical circuit including the Anterior Cingulate Cortex (ACC), among other areas [11]. Research has also shown abnormalities in ACC neuronal functioning in anxiety [12]. Accordingly, we hypothesized that stimulating the ACC with TMS would facilitate improved reactivity of this circuit, thereby improving response to ketamine. We report on a patient with refractory major depressive disorder comorbid with chronic pain, iatrogenic neurotoxicity and suicidal ideation, who had not responded to numerous types of psychotropic and pain medicine, but showed remarkable results after treatment with the novel TMS/ketamine combination therapy [3,13,14].

## CASE PRESENTATION

The patient was a 62-year-old Caucasian female working in the nursing field and presenting on the verge of suicide. Following episodes of ETOH abuse, history of multiple medication trials, physical pain and prolonged family stressors (progressive illness and eventual death of husband), intense grief, she had been considered as treatment non-responsive following multiple treatment failures.

Her formal diagnoses were TRD (Treatment Resistant Depression) and the effects of poly pharmacy, which had been prescribed to address her suffering. The neurological exam was within normal limits and did not suggest focal neurological dysfunction of the Central Nervous System. She had been treated with varied pharmacological interventions but, during this time, her symptoms did not respond to algorithm-driven pharmacologic management. Before beginning combination TMS/ketamine therapy the patient was assessed, using well-validated measures of anxiety (Oasis), life satisfaction (LSR), depression and suicidality (PHQ-9). Marked impairment was indicated (OASIS = 0; PHQ-9 = 25 and LSI = 12)

and tapered down to 225mg at the last treatment. To attenuate anxiety during treatment, anxiolytics were given on an as-needed basis (Versed 1-2 mg). During pretreatment and combination therapy, the TMS head coil (manufactured by Neotonus) was positioned at the midline of the anterior scalp to achieve maximal stimulation of the medial prefrontal area that overlays the anterior cingulate cortex, a region implicated in depression and anxiety [6,7,12]. TMS treatments were administered at 115% of motor threshold at 1Hz continuous pulsation settings established to be within safety guidelines and consistent with our protocol in use for over three years [3,13,14]. Using this method, we hypothesized



**Figure 1:** Brain SPECT functional imaging results, pre and post treatment. The first two columns show 2/8 images from the stereotactic surface projections obtained via the Neurostat software (16) with our own color code. The next two columns are representative of the orthogonal sections display. The last two columns show thresholded volumetric displays (threshold=67%). The upper row is the baseline display (before treatment). The lower row shows the follow-up display, 5months later. In the mean while, the patient underwent a series of 30TMS/ketamine combination treatments. At post-treatment there are major perfusion improvements, involving all-cortical and subcortical structures.

She also underwent functional brain imaging with SPECT (15-17) using 99mTc Ceretec (HMPAO). Resulting images showed extensive bilateral hypo-perfusion involving all lobes (see Figure 1).

that the network effects of ketamine regulated by TMS would facilitate activation of the anterior cingulate and help re-establish normal oscillatory rhythms in this region [11], leading to a decrease in depression and anxiety symptoms.

### Preand post Combination therapy with TMS/ketamine

Her formal diagnoses were TRD (Treatment Resistant Depression) and the effects of poly pharmacy, which had been prescribed to address her suffering. The neurological exam was within normal limits and did not suggest focal neurological dysfunction of the Central Nervous System. She had been treated with varied pharmacological interventions but, during this time, her symptoms did not respond to algorithm-driven pharmacologic management. Before beginning combination TMS/ketamine therapy the patient was assessed, using well-validated measures of anxiety (Oasis), life satisfaction (LSR), depression and suicidality (PHQ-9). Marked impairment was indicated (OASIS = 0; PHQ-9 = 25 and LSI = 12)

After five months of weekly treatments, the patient reported markedly improved symptoms a dramatic clinical improvement leading to major changes in her daily life: enthusiastic, rational, planning for future, taking charge of her financial and family situation and a renewed religious sentiment. Repeat psychological testing reflected major improvement after six months of treatment. She reported being free of anxiety, depression, and suicidality (OASIS = 0, PHQ-9 = 1). Moreover, she reported herself to be extremely satisfied with her life circumstances (LSI = 35). As additional observation we noticed that she did not complain about pain anymore.

She also underwent functional brain imaging with SPECT (15-17) using 99mTc Ceretec (HMPAO). Resulting images showed extensive bilateral hypo-perfusion involving all lobes (see Figure 1).

At long-term follow-up the patient had been practically free of suffering for almost three years.

The treatment initiated was based on the patented combination therapy developed by one of us [3]. The protocol of treatment included two days of TMS pre-treatment (4 treatments per day of 30minutes each with 45 minutes of rest between treatments). Combination TMS/ketamine infusion therapy [3,13,14] began the following day and continued once per week for 30 weeks. Three years of observational evidence from the treatment provided to numerous patients in our clinic suggested that this duration would produce clinically significant results. An application of this form of treatment consisted of 40 minutes of 1Hz continuous TMS with a concurrent intravenous ketamine infusion bracketed within the middle 30 minutes of TMS, resulting in five minutes of TMS alone pre- and post-infusion. The dosage of infused ketamine increased gradually from 50mg at the first treatment to a peak of 250mg at the tenth treatment,

A repeat post-treatment brain SPECT functional imaging showed markedly improved perfusion across the board in cortical and sub cortical structures (see Figure 1).

### DISCUSSION

This case report presents the therapeutic strategy aimed at addressing complex cluster of symptoms occurring in comorbidity of psychiatric and somatic disorders (depression, anxiety and pain). While existing research has indicated that TMS is somewhat effective in treating depression and anxiety [4,5,8], and that ketamine produces short-term relief from depression and anxiety [9-10], it is the combination therapy using concurrent TMS and ketamine infusion that achieved the results in this case. We believe that modulation of the known dysfunctional cortico-thalamo-cortical circuit via the entraining effect of electromagnetic

stimulation rendered this patient more responsive to the ketamine infusion. This resulted in more efficacious relief from the refractory depression and comorbid anxiety, as well as improvement of the somatic component (chronic pain). The result appears to be enduring, as the patient has been free of suffering for almost 3 years.

This latter effect is substantiated by our present clinical experience with similar cases as well as by a recent review that points to the relation between mental disorders and chronic physical conditions, as well as the need to integrate their treatment [18].

The favorable effect of the combination therapy is further emphasized by the substantial and widespread improvement of cortical perfusion on brain SPECT functional imaging. Future work is in progress to further evaluate the efficacy of this treatment on a larger patient population.

### CONCLUSION

This case presentation points to the clinical efficacy of a novel combination therapy of concurrent TMS along with ketamine infusion in a case of treatment-refractory depression, with suicidal ideation and comorbid with chronic pain and iatrogenic neurotoxicity. The favorable results were obtained despite years of unsuccessful previous treatments. The clinical improvements were also substantiated by the major increases in cortical and subcortical perfusion, as seen on brain SPECT imaging.

### REFERENCES

- 1 Sackeim HA. (2001). The definition and meaning of treatment-resistant depression. *J Clin Psych.* 62: 10-17.
- 2 Crown WH, Finkelstein S, Berndt ER, Ling D, Poret AW, et al. (2002). The impact of treatment-resistant depression on health care utilization and costs. *J Clin Psych.* 63: 963-971.
- 3 Best SRD. (2014). Rapid relief of treatment resistant depression by facilitated ketamine infusion: A preliminary report. *Activitas Nervosa Superior.* 56: 28-36.
- 4 Gross M, Nakamura L, Pascual-Leone A, Fregni F. (2007). Has repetitive transcranial magnetic stimulation (TMS) treatment for depression improved? A systematic review and meta-analysis comparing the recent vs. the earlier TMS studies. *Acta Psychiatrica Scandinavica.* 116: 165-173.
- 5 Zwanger P, Minov C, Ella R, Schule C, Baghai T, et al. (2014). Transcranial magnetic stimulation for panic. *Am J Psych.* 159: 315-326.
- 6 Chang CC, Yu SC, McQuoid DR, Messer DF, Taylor WD, et al. (2011). Reduction of dorsolateral prefrontal cortex gray matter in late-life depression. *Psychiatry Res. Neuroimaging.* 193: 1-6.
- 7 Smith R, Chen K, Baxter L, Fort C, Lane RD. (2013). Antidepressant effects of sertraline associated with volume increases in dorsolateral prefrontal cortex. *J Affect Disord.* 146: 414-419.
- 8 Cohen H, Kaplan Z, Kotler M, Kouperman I, Moisa R, et al. (2004). Repetitive transcranial magnetic stimulation of the right dorsolateral prefrontal cortex in posttraumatic stress disorder: a double-blind, placebo-controlled study. *Am J Psych.* 161: 515-524.
- 9 Berman RM, Cappiello A, Anand A, Oren DA, Heninger GR, et al. (2000). Antidepressant effects of ketamine in depressed patients. *Biol Psychiatry.* 47: 351-354.
- 10 Ionescu DF, Luckenbaugh DA, Niciu MJ, Richards EM, Zarate CA. (2014). A single infusion of ketamine improves depression scores in patients with anxious bipolar depression. *Bipolar Disorders.* 17: 438-443.
- 11 Llínas RR, Ribary U, Jeanmond D, Kronberg E, Mitra PP. (1999). Thalamocortical dysrhythmia: A neurological and neuropsychiatric syndrome characterized by magnetoencephalography. *Proc Natl Acad Sci.* 96: 15222-15227.
- 12 Etkin A, Prater KE, Hoefl F, Menon V, Schatzberg AF. (2010). Failure of anterior cingulate activation and connectivity with the amygdala during implicit regulation of emotional processing in generalized anxiety disorder. *Am J Psych.* 167: 545-554.
- 13 Best SRD. (2014). Combined ketamine/transcranial magnetic stimulation treatment of severe depression in bipolar I disorder. *Journal of ECT.* 30: 50-51.
- 14 Best SRD. (2015). Combined ketamine and transcranial magnetic stimulation for treatment resistant depression in the context of chronic OCD: A case report. *Neuropsychiatric Electrophysiology.* 1: 2.
- 15 Catafau AM. (2001). Brain SPECT in clinical practice. Part I: perfusion. *J. Nucl. Med.* 42: 259-271.
- 16 Minoshima S, Koeppe RA, Frey KA, Kuhl DE. (1994). Anatomical standardization: linear scaling and nonlinear warping of functional brain images. *J. Nucl. Med.* 35: 1528-1537.
- 17 Juni JE, Waxman AD, Devous MD, Tikofsky RS, Ichise M, et al. (2009). Procedure guidelines for brain perfusion SPECT using 99mTc radiopharmaceuticals 3.0. *J. Nucl. Med. Tech.* 37: 191-195.
- 18 Scott KM, Lim C, Al-Hamzawi A, Alonso J, Bruffaerts R, et al. (2016). Association of mental disorders with subsequent chronic physical conditions: World mental health surveys from 17 countries. *JAMA Psych.* 73: 150-158.
- 19 Niesters M, Martini C, Dahan A. (2014). Ketamine for chronic pain: risks and benefits. *British Journal of Clinical Pharmacology.* 77: 357-367.