

Paracetamol (Acetaminophen), Alcohol and Liver Injury: Biomarkers, Clinical Issues, and Experimental Aspects

Rolf Teschke^{1*} and Yun Zhu²

¹Department of Internal Medicine II, Division of Gastroenterology and Hepatology, Klinikum Hanau, Hanau, Academic Teaching Hospital of the Medical Faculty, Goethe University Frankfurt/ Main, Frankfurt/Main, Germany

²Integrative Medical Center and China Military Institute of Chinese Medicine, 302 Military Hospital, Beijing, China

ARTICLE INFO

Received Date: September 22, 2018

Accepted Date: October 24, 2018

Published Date: October 29, 2018

KEYWORDS

Acetaminophen

Paracetamol

Alcohol

Drug induced liver injury

Roussel Uclaf Causality Assessment

Method

Cytochrome P450 2E1

ABSTRACT

Acute liver failure (ALF) after ingestion of overdosed paracetamol (syn. acetaminophen) can partially be prevented if N-Acetylcysteine (NAC) is early administered as a specific antidote to restore hepatic glutathione levels. These are reduced during paracetamol intoxication due to scavenging toxic intermediates generated through the metabolic action of hepatic microsomal cytochrome P450 (CYP), preferentially its isoenzyme 2E1. Despite NAC based therapeutic options, ALF by overdosed paracetamol is commonly observed and assumed as a major indication of liver transplantation, although causality is rarely established using robust methods such as RUCAM (Roussel Uclaf Causality Assessment Method) that would facilitate exclusion of alternative causes. Specific biomarkers can help ensure that paracetamol was ingested but they do not prove that paracetamol was implicated in drug induced liver injury. Overdosed paracetamol commonly causes intrinsic liver injury, whereas at normal doses it may rarely lead to idiosyncratic liver injury, in analogy to many commonly used drugs, or even cause liver adaptation, a mild hepatic involvement due to paracetamol use. Clinical experience suggests that alcoholics are more susceptible to liver injury by paracetamol, supported experimentally using a pair-feeding model of alcohol administration. Finally, chronic alcohol consumption upregulates CYP 2E1, stimulating the microsomal metabolism of paracetamol and ethanol. In conclusion, liver injury by paracetamol is complex, requiring full clinical attention.

ABBREVIATIONS

ALT: Alanine Transaminase; AST: Aspartate Transaminase; CLD: Chronic Liver Diseases; CYP: Cytochrome P450; CYP2E1: Cytochrome P450 2E1; DILI: Drug Induced Liver Injury; GDH: Glutamate Dehydrogenase; GGT: Gamma-Glutamyl Transferase; HBV: Hepatitis B Virus; HCV: Hepatitis C Virus; HILI: Herb Induced Liver Injury; NAFLD: Nonalcoholic Fatty Liver Disease; NASH: Nonalcoholic Steatohepatitis; PMH: Past Medical History; ROS: Reactive Oxygen Species; RUCAM: Roussel Uclaf Causality Assessment Method

INTRODUCTION

The worldwide use of paracetamol (acetaminophen, N-acetyl-p-aminophenol, APAP, Tylenol®) is overwhelming, as evidenced by the large number of liver injury cases including acute liver failure (ALF) and comprehensively referenced [1,2]. The high

Copyright: © 2018 Teschke R et al., SL Pharmacology and Toxicology This is an open access article distributed under the Creative Commons Attribution License, which permits unrestricted use, distribution, and reproduction in any medium, provided the original work is properly cited.

Citation for this article: Rolf Teschke. Paracetamol (Acetaminophen), Alcohol and Liver Injury: Biomarkers, Clinical Issues, and Experimental Aspects. SL Pharmacology and Toxicology. 2018; 1(1):113

Corresponding author:

Rolf Teschke

Department of Internal Medicine II, Klinikum Hanau, Hanau, Germany, Tel: +49-6181/21859; Fax: +49-6181/2964211;

Email: rolf.teschke@gmx.de

appreciation of this drug is due to its assumed analgesic and antipyretic properties, although a cochrane analysis clearly summarizes concerning paracetamol: widely used and largely ineffective [3]. Of interest is another figure: Global paracetamol market set for rapid growth to reach around US \$999.4 million by 2020, a veritable number although some percentages must be ascribed to non-medicinal use of paracetamol for various applications such as dye and chemical industries; an increase is expected for the volume of paracetamol, estimated at 149.3 kilotons in 2014 [4]. There is also the note for the United Kingdom regarding an estimate of the amount of paracetamol sold that is just under 6.300 tons a year, corresponding to 35 tons per one million of population, equating to 35 grams paracetamol or 70 paracetamol tablets averaging for each inhabitant, for every year. Other concerns focus on health and economic consequences of liver injury by paracetamol, responsible for annually almost 500 deaths in the US alone, 100.000 calls to the US Poison Control Centers, 50.000 emergency room visits, and 10.000 hospital admissions [5]. This led to the question, isn't it appropriate to call for more regulations, and isn't it time for APAP to go away? [5]. Although challenging and of high interest for regulatory agencies such as the US FDA, discussing these aspects in detail is outside the aim of this review article.

The focus of the present analysis is instead on other issues and relates to the impact of alcohol on liver injury by paracetamol including experimental evidence that chronic alcohol consumption aggravates liver injury due to paracetamol, and its role of hepatic microsomal cytochrome P450 2E1, the isoenzyme that is involved in both, ethanol metabolism via the microsomal ethanol oxidizing system (MEOS) and enzymatic paracetamol degradation. Under discussion are also questions of valid diagnostic biomarkers, approaches of causality assessment in suspected ALF by paracetamol, and to what extent paracetamol causes liver test elevations below the threshold criteria for classical liver injury, reflecting liver adaptation rather than liver injury.

LITERATURE SEARCH AND SOURCE

The PubMed database was used to identify publications for the following terms: Paracetamol, acetaminophen, alcohol, liver injury, liver disease, and combinations thereof. Limited to

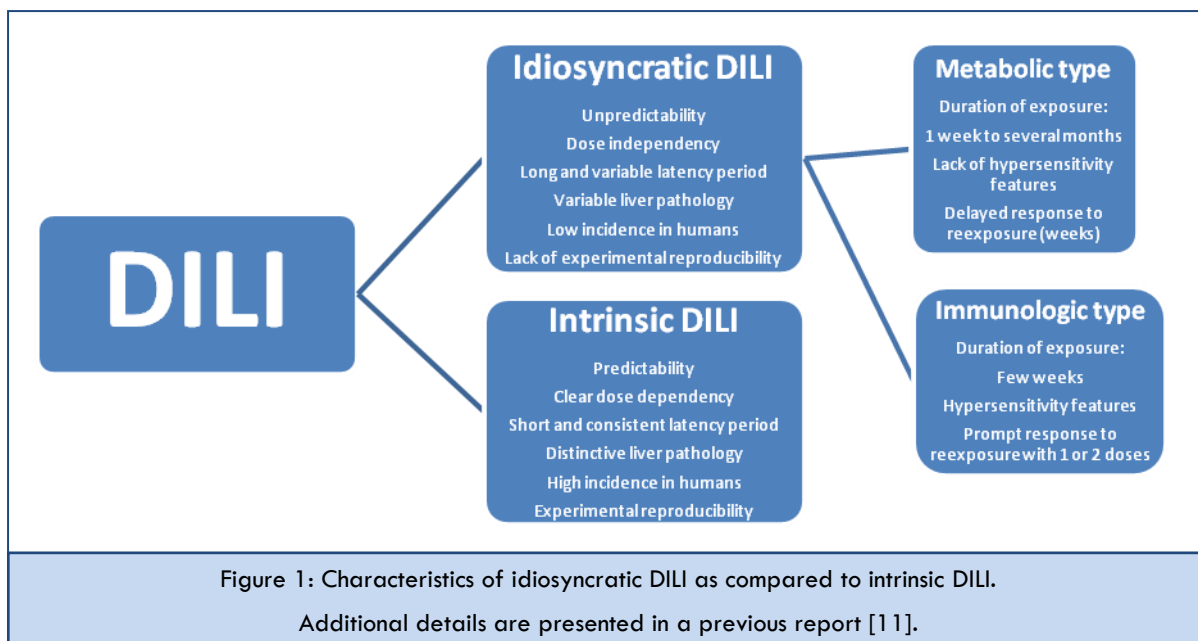
English language, publications of the first 50 hits from each searched segment were analyzed for suitability of this review article. The search for additional publications was completed on 4 September 2018. The final compilation consisted of original papers, consensus reports, and review articles. The most relevant publications were included in the reference list of this review.

LIVER INJURY CLASSIFICATION AND LIVER ADAPTATION

Consensus exists that liver injury by drugs is defined as threshold values for the liver tests (LT) Alanine aminotransferase (ALT) and Alkaline phosphatase (ALP), with serum activities for $ALT \geq 5 \times ULN$ (upper limit of normal) and $ALP \geq 2 \times ULN$ [6-10]. Respective values for liver adaptation caused by drugs are below these thresholds of liver injury [10].

Idiosyncratic versus intrinsic toxicity

The use of conventional drugs rarely leads to liver injury, whether the toxicity is due to the interaction between the drug and patient factors (idiosyncrasy) causing idiosyncratic drug induced liver injury, or due to the drug only (intrinsic toxicity) causing intrinsic drug induced liver injury [11]. For reasons of clarity, DILI commonly stands for idiosyncratic DILI, which is caused by drugs at therapeutic or near therapeutic dosages in a few exposed patients and triggered by unpredictable, mostly immunologic and less frequently metabolic drug reactions (Figure 1). This is in contrast to intrinsic DILI characterized by a clear dose dependent and therefore predictable reaction, observed in many patients with overdosed drugs such as acetaminophen (Figure 1) [11]. Idiosyncratic and intrinsic DILI share with ALF the risk of high mortality rates or need of liver transplantation [1,2,5,9-18]. The most commonly used drugs cause rare idiosyncratic DILI [6-17], only few drugs are causes of intrinsic DILI [1,2,5]. Interestingly, our actual analysis of published cases or case series clearly shows that using paracetamol three different types of liver involvement can be observed: liver adaptation (rare), idiosyncratic DILI (also rare), and intrinsic DILI (most common). Such interpretation is indeed new, has not been discussed before, was neglected, or ignored. However, these different types merit more clinical attention as clinical features are different and require different clinical approaches.



DILI: Drug induced liver injury.

Liver adaptation

Contrasting with liver injury and its potentially high LTs, liver involvement during use of few drugs may also be characterized by liver adaptation or tolerance with mild LT increases, remaining below the threshold values of liver injury [10,11]. Adaptation is observed during treatment with drugs

such as statins and antituberculous medications especially INH (Isonicotinic acid hydracide). Despite drug use continuation, LTs remain stable or return to normal range, but this initial favorable condition should not exclude the drug as a likely cause of acute liver injury in the further course [10].

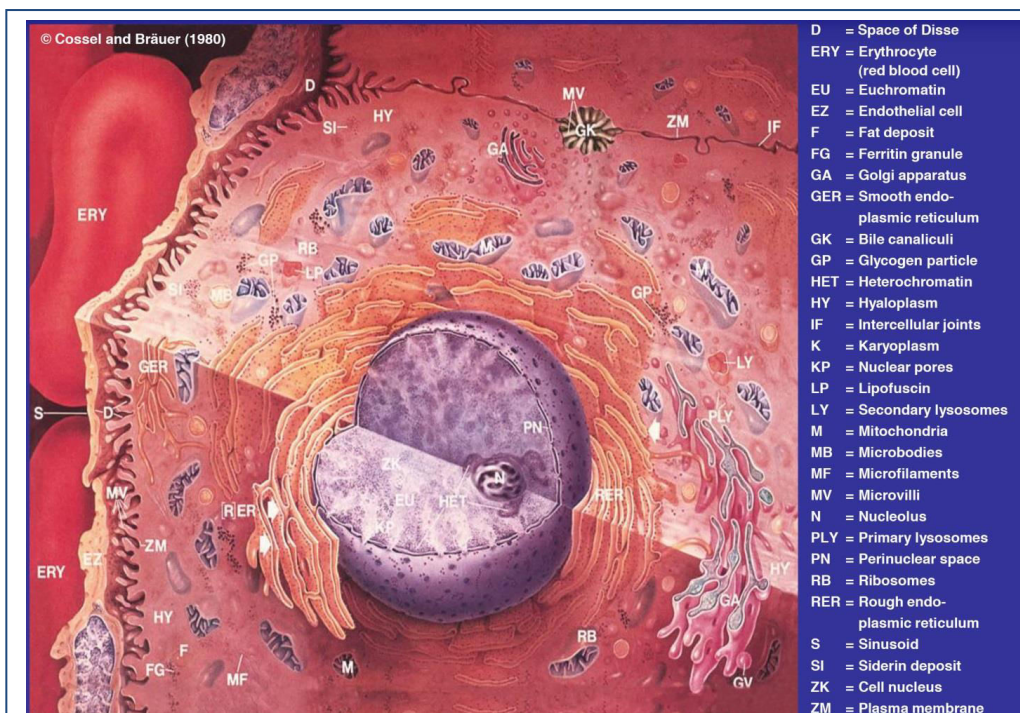

Figure 2: Normal human liver cell with cell organelles within the cytoplasm. Figure adapted and translated from an illustration of L. Cossel and H. Bräuer, Excerptahepatologica – Bildatlas zur Physiologie und Pathophysiologie der Leber – Band 1, 1980, Cascan Corp., previously Wiesbaden now Dresden (Germany), with permission of Cascan Corp, Dresden.

METABOLIC CONSIDERATIONS

Enzymatic reactions help metabolize drugs and ethanol and are confined to the hepatocyte with its endoplasmic reticulum (Figure 2), which corresponds to the microsomal fraction obtained by ultracentrifugation of liver homogenates of the biochemists. In line with many drugs and exogenous compounds, alcohol and paracetamol [1,2] share a common metabolic pathway, involving the isoenzyme 2E1 of the hepatic microsomal cytochrome P450 (CYP) that is transferred from the oxidized to its reduced state through the action of the

microsomal NADPH-cytochrome P450 reductase (Figure 3). Substrates entering the cytochrome P450 circle are commonly converted to oxidized substrates (Figure 4), a process associated with the risk of toxic radical formation (Table 1). Such sequences of events help clarify clinical relevant interactions between these two chemicals at the site of cytochrome P450 and explain the molecular basis of paracetamol induced liver injury of patients with alcohol problems.

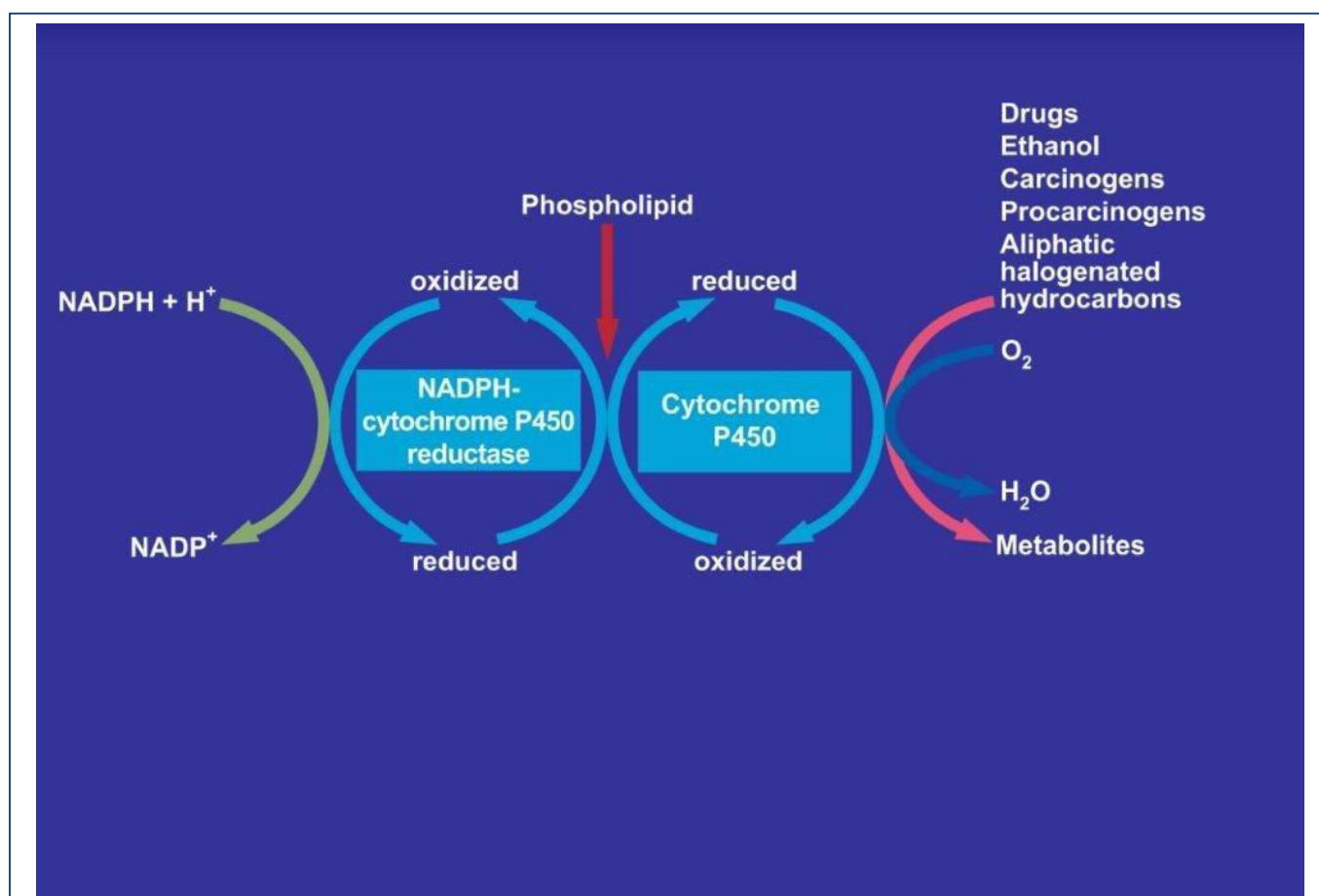


Figure 3: Involvement of cytochrome P450 in the microsomal metabolism of various substrates including aliphatic halogenated hydrocarbons with carbon tetrachloride as example. The NADPH-cytochrome P450 uses NADPH + H⁺ and will itself be reduced, allowing the cytochrome P450 to be transferred from the oxidized state to the reduced state. The overall reactions need also molecular oxygen and phospholipids. Additional details are presented in a previous report [19].

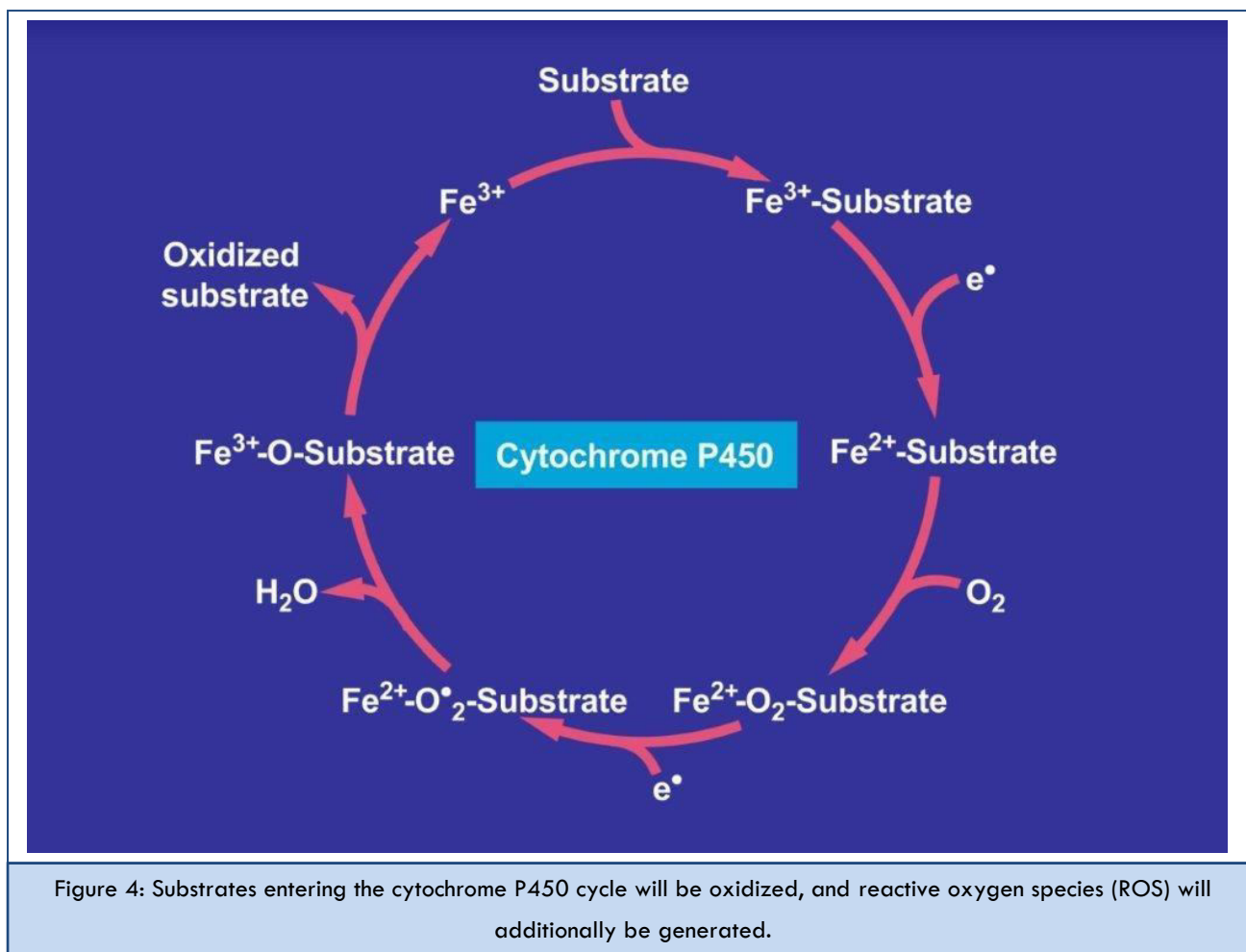


Figure 4: Substrates entering the cytochrome P450 cycle will be oxidized, and reactive oxygen species (ROS) will additionally be generated.

Selected potentially toxic intermediates and reactive O ₂ -species during microsomal drug metabolism
Singlet radical ¹ O ₂
Superoxide radical HO ₂ [•]
Hydrogen peroxide H ₂ O ₂
Hydroxyl radical HO [•]
Alkoxy radical RO [•]
Peroxy radical ROO [•]
Lipid peroxides

Some toxic intermediates generate lipid peroxides through direct reaction with phospholipids of subcellular membranes.

Alcohol

In addition to alcohol metabolism via cytosolic alcohol dehydrogenase (ADH) proceeding at low alcohol concentrations, the hepatic microsomal ethanol oxidizing system (MEOS) converts ethanol to acetaldehyde preferentially at higher alcohol concentrations and following chronic alcohol consumption that upregulates CYP 2E1 [19-24]. This is an

essential constituent of MEOS, which increases in activity, enhances alcohol metabolism, and accelerates the production of reactive oxygen radicals (ROS) and other toxic intermediates [19]. In alcoholic liver disease hepatic glutathione levels are reduced [25], likely due to scavenging these intermediates or because of preexisting malnutrition.

Paracetamol

In analogy to ethanol, paracetamol is also partially metabolized by hepatic microsomal CYP 2E1 (Figure 5) [1], a pathway that becomes activated if paracetamol conjugation with sulfate and glucuronide is exhausted, both of which commonly take care of paracetamol degradation by 90% especially in paracetamol overdose [1,2]. However, the CYP dependent paracetamol degradation leads to the formation of

ROS and other toxic intermediates such as N-Acetyl-P-Benzoquinone Imine (NAPQI) [2], which are detoxified by combining with hepatic glutathione, provided it is available in sufficient amounts [1,2]. With increasing usage of glutathione and associated exhaustion of the hepatic glutathione, toxic intermediates including NAPQI are not any more bound to glutathione but rather bind to cell macromolecules and initiate mitochondrial injury [2], apoptosis, and liver cell necrosis [1,2].

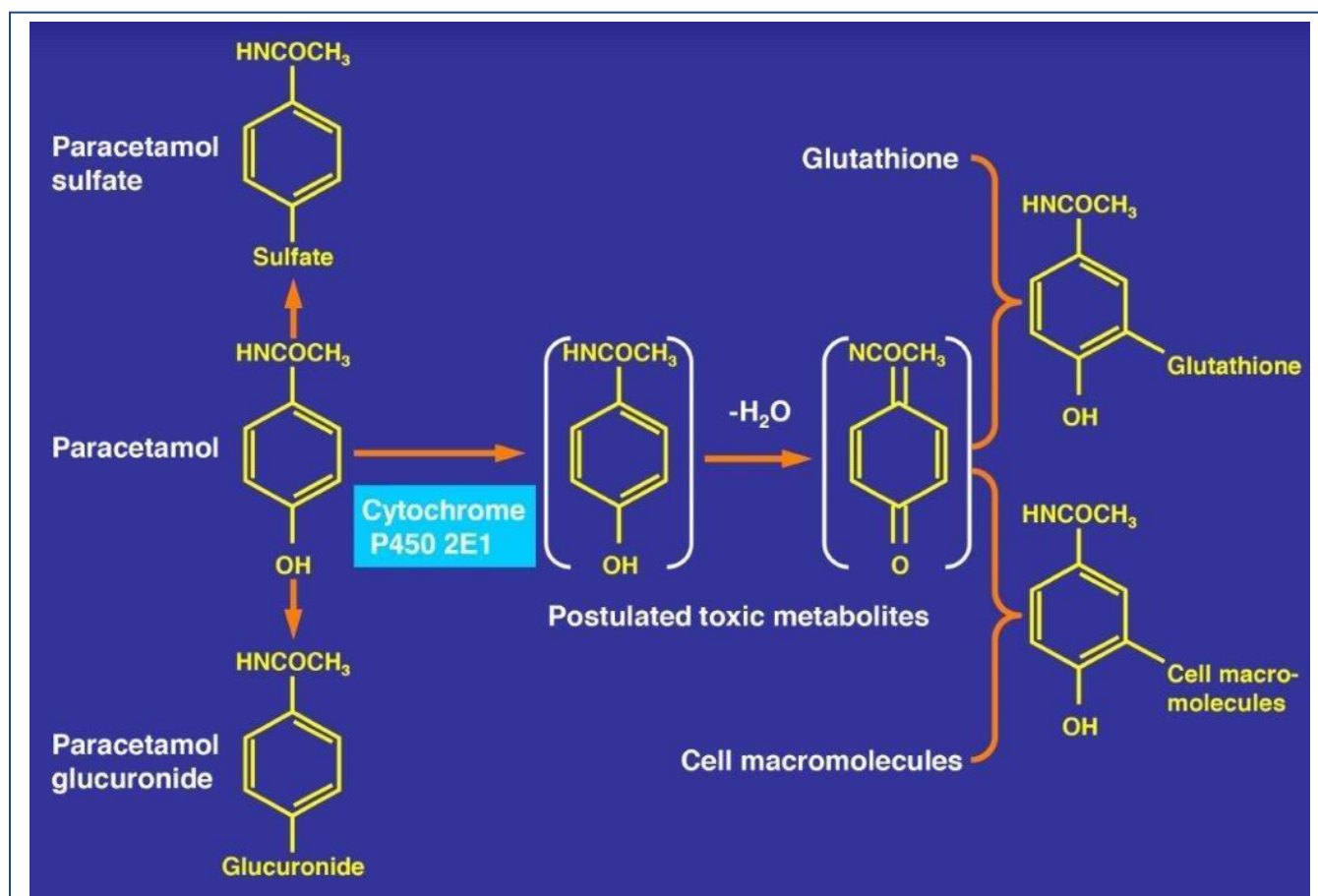
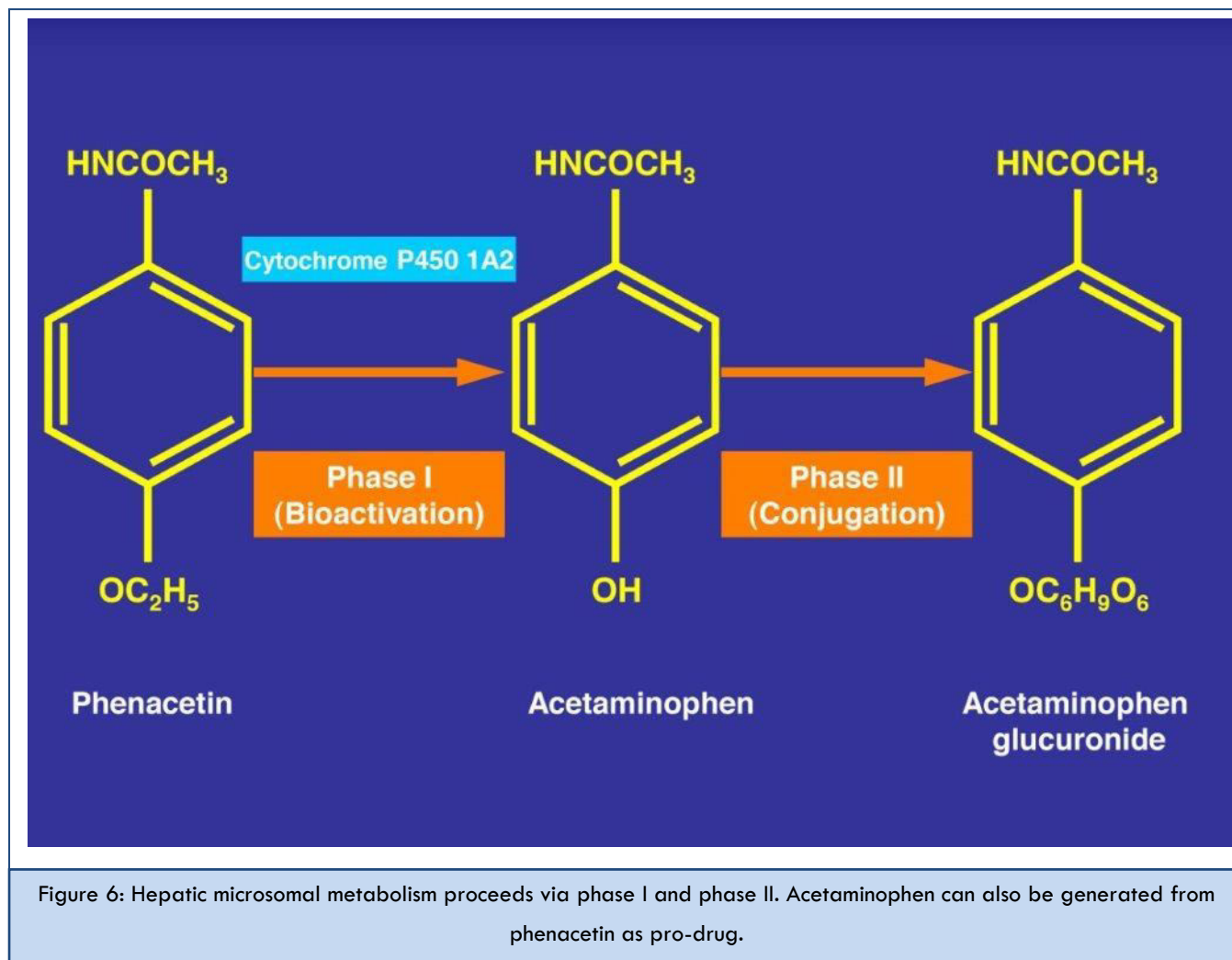


Figure 5: Metabolism of paracetamol in hepatic microsomes. Conjugation products include the non-toxic paracetamol sulfate and paracetamol glucuronide, whereas toxic metabolites are generated via cytochrome P450 2E1.

Paracetamol can be ingested as parent chemical but it may also be generated from phenacetin [26] through a Phase I reaction involving CYP 1A2 (Figure 6), another CYP isoenzyme different from 2E1 and with other substrate specificities.



BIOMARKERS

For the diagnosis of idiosyncratic and intrinsic DILI by a variety of drugs, several diagnostic biomarkers have been proposed [27]. For instance, under discussion are CK-18 (Cytokeratin-18), microRNA-122 (microarray RNA-122), total HMGB-1 (High mobility group box protein-1), GDH (Glutamate dehydrogenase), SDH (Sorbitol dehydrogenase) proposed as marker for hepatocyte necrosis, ccCK-18 (caspase-cleaved CytoKeratin-18) proposed as marker for apoptosis, hyperacetylated HMGB-1, and MCSFR-1 (Macrophage colony-stimulating factor receptor-1) proposed as marker for immune activation [27]. Other proposals included M-30 (apoptosis), M-65 (apoptosis/necrosis), and microRNA-192 (unspecified liver damage). Some of the proposed biomarkers are not liver or not drug specific, others are difficult to be assessed due to the requirement of mass spectroscopy [27].

Microarray RNAs (microRNAs) including microRNA-122 have been evaluated in experimental liver injury and in human intrinsic DILI caused by paracetamol, but uncertainty exists on their diagnostic value due to lacking information of the used method assessing causality. Additional studies focused on paracetamol protein adducts in the serum, generated during paracetamol metabolism involving reactive intermediates that bind to cellular proteins [28-31]. Such protein adducts primarily indicate that the patient under consideration had used paracetamol and their diagnostic value certainly is higher than simple paracetamol determinations in the blood, which has a narrow diagnostic window due to rapid clearance after ingestion. Biomarkers cannot solve the problems of alternative diagnoses commonly confounding DILI [11]. It seems that cases of DILI by paracetamol used for testing new biomarkers are not correctly assessed by a validated causality assessment

method (CAM), an omission that substantially decreases the power of the tested biomarker [27]. Here assessment by RUCAM (Roussel Uclaf Causality Assessment Method) [7] will ensure homogeneity of cases tested with the new biomarker. Diagnostic biomarkers as blood (or urine) tests would be of great help for clinicians and regulators, and pharmaceutical industry would be more comfortable if, in addition to RUCAM, causality of DILI can be objectively confirmed [27].

Although various biomarkers are under study, a more practical diagnostic approach is required for patients with an acute single paracetamol overdose to classify the potential risk of toxicity [1]. Most commonly used is the classic Rumack-Matthew monogram of paracetamol concentration to time from ingestion, applicable when the time of paracetamol ingestion is known and occurred within the preceding 24 hours. Plotting the time in hours versus paracetamol levels provides points on the “probable toxicity line”; important are paracetamol levels of 200 $\mu\text{g}/\text{ml}$ at 4 hours and 25 $\mu\text{g}/\text{ml}$ at 16 hours following acute intake [1]. Patients presenting higher paracetamol levels are at risk of severe liver injury as defined with ALT >1000 U/L and require NAC treatment.

CLINICAL ISSUES

Paracetamol, liver disease and hepatic adaptation

Recommended maximum daily doses of paracetamol are 4g for the general population not conflicted by an alcohol issue [32,33], and paracetamol at a single dose of 325mg to 500mg likely will not cause acute DILI in patients with an alcohol problem or known alcoholic liver disease [1]. In analogy to alcohol, a variety of other nutritional conditions may upregulate hepatic microsomal CYP2E [11,19-24,34-41] and thereby increase the formation of toxic intermediates from enzymatic paracetamol degradation, at least on theoretical grounds. But this possible risk is insufficiently investigated and there is presently lacking evidence whether a reduction of daily or single paracetamol doses is required for these conditions.

Analysis of published cases reveals that paracetamol at high single doses, typically 15g or more, may cause the classic intrinsic DILI including ALF [2], but at lower doses, paracetamol use leads also to idiosyncratic DILI as well as liver adaptation [1,2,32,33]. Intrinsic and idiosyncratic DILI by paracetamol are

both defined by ALT values $\geq 5 \times \text{ULN}$, not allowing for differentiation of these two types of injury from each other; however, dissociation is possible by the amount of paracetamol ingested, overdose causes intrinsic liver injury and recommended daily doses may cause idiosyncratic injury. Liver adaptation presents with ALT $< 5 \times \text{ULN}$ and occurs mainly at recommended paracetamol doses.

As expected, the number of published cases with idiosyncratic DILI due to paracetamol is much smaller [32,33] compared to the large number of intrinsic DILI and ALF due to overdosed paracetamol [1,2]. In an excellent prospective study, some specific characteristics of 7 patients were described for idiosyncratic DILI due to acetaminophen when used at therapeutic daily doses ranging from 500mg to 3250mg; the pattern of use was variable ranging from once a week for years, daily for 1 day or up to 22 days, and a latency period from last use until onset may be in a narrow range from 11 to 13 days [33]. Neglect of this long latency period impairs identifying paracetamol as cause in patients with unknown increased LTs [42,43]. Of clinical importance in idiosyncratic DILI by paracetamol are immunological signs, which may include rash, eosinophilia, arthralgia, fever, and thrombocytopenia [33]. Respective cases were assessed for causality using RUCAM, and case data were obtained from a prospective study carried out in Spain [15]. In the US study on idiosyncratic DILI by paracetamol, causality for paracetamol was not assessed by a robust CAM [32] such as RUCAM [44,45]. Clearly, future cases should be assessed for causality using the updated RUCAM version [7,8].

As opposed to the intrinsic or idiosyncratic DILI connected with the use of overdosed or normal dosed paracetamol, liver adaptation may occur with paracetamol at therapeutic doses in a few patients [32]. This condition presents without symptoms and is therefore of little clinical interest as long as liver tests like ALT remain in the lower range with $< 5 \times \text{ULN}$; in most of these patients, ALT will gradually fall to normal values, and clinical decisions are not required. Liver adaptation is also known for other drugs such as statins and antituberculous medications [10,13].

Risk factors and confounding variables

Overweight and obesity: Paracetamol is commonly used by patients with obesity or morbid obesity. They often are

multimorbid as evidenced by their PMH (past medical history) and the documented high number of prescribed drugs, classifying these as multimedicated patients [42,43,46]. Suffering from a multipain syndrome consisting mainly of muscular-skeletal and osteoarthritic pains or migraine, they appreciate paracetamol for pain relief [42,43,47,48], in addition to other drugs [42,43,46,47].

Patients suffering from overweight as evidenced by a body mass index (BMI) between 25 and 30 kg/m², obesity with a BMI of at least 30 kg/m² [49,50], or rarely also morbid obesity, often are confronted with associated nonalcoholic fatty liver disease (NAFLD) or nonalcoholic steatohepatitis (NASH), potential precursors of more rare cirrhosis and hepatocellular carcinoma (HCC) [50]. These different types of liver diseases may lead to some increase of serum ALT activities [51], often similar to ALT values observed in patients, who used normal dosed paracetamol [32]. Consequently, all obese patients with new serum ALT elevations during any treatment by paracetamol require a professional clarification whether this increase is due to the obesity disorder itself or the new treatment [48,50].

Obesity-based liver diseases exhibit increased hepatic microsomal CYP 2E1 contents due to upregulation [38-40,50,52], similar to chronic alcohol consumption [19-24,34-41,52,53]. This CYP 2E1 upregulation is also typical for other conditions [36-40,52,53], such as metabolic syndrome, diabetes mellitus, acetone-based starvation, and known as a clinical risk factor of increased liver injury caused for instance by carbon tetrachloride [53-57] or halothane [53].

Chronic alcohol abuse: Alcohol problems are well documented for patients experiencing increased serum ALT activities following paracetamol use; this led to the conclusion that alcohol abuse and alcoholic liver disease may be risk factors of paracetamol-induced liver injury. However, defining the

respective quantitative risk under usual clinical conditions is difficult for various reasons: (1) a homogenous study cohort is rarely available, (2) acute ingestion of paracetamol concomitant with alcohol attenuates liver injury by paracetamol, likely through metabolic competition at the site of CYP 2E1, (3) variability of the amount of paracetamol ingested, (4) variability of therapy conditions and antidote efficacy, (5) preexisting liver disease, and (6) concomitant medication.

Comedication: Substantial comedication is a typical feature in patients using paracetamol [33]. Some of the comedicated drugs were potentially hepatotoxic but all received a RUCAM-based causality grading that was lower than that for paracetamol, which itself had to be implicated in causing the liver injury.

Diagnostic challenges

Insufficient product identification is a serious problem because patients are often not aware that they took paracetamol, especially if it is one of several ingredients of a drug they consumed. Consequently, some paracetamol induced liver injury cases will remain undetected. On the other hand, in 34% of initially assumed DILI cases, liver injury was not related to a drug and had to be attributed to other causes [11], but respective data for cases wrongly attributed to paracetamol are not available. The best approach to exclude alternative causes would be the use of a transparent scoring CAM such as RUCAM in its updated version [7,8]. Even worse, for overall 47% of the drugs listed in the US LiverTox database assumed as causing DILI did in fact not have evidence of hepatotoxicity as partially assessed by the updated RUCAM [58], substantiating problems to classify DILI cases as real DILI. In fact, exclusion of alternative causes in suspected DILI cases is mandatory, best achieved using prospectively the check list of differential diagnoses (Table 2) and the updated RIUCAM [7].

Table 2: Checklist of differential diagnoses of DILI.

Differential diagnosis	Diagnostic parameters	Done		
		Yes	No	Partially
Group I				
Hepatitis A virus (HAV)	Anti-HAV-IgM	<input type="checkbox"/>	<input type="checkbox"/>	<input type="checkbox"/>
Hepatitis B virus (HBV) (Hepatitis D virus, HDV)	anti-HBc-IgM and HBV-DNA (specific marker of HDV)	<input type="checkbox"/>	<input type="checkbox"/>	<input type="checkbox"/>
Hepatitis C virus (HCV)	anti-HCV and HCV-RNA	<input type="checkbox"/>	<input type="checkbox"/>	<input type="checkbox"/>
Hepatitis E virus (HEV)	anti-HEV-IgM and HEV-RNA	<input type="checkbox"/>	<input type="checkbox"/>	<input type="checkbox"/>

Ischemic liver necrosis	Episode of severe hypotension, shock, hypoxia or heart failure within 3 days before the onset of liver injury	<input type="checkbox"/>	<input type="checkbox"/>	<input type="checkbox"/>
Biliary obstruction	Liver imaging (e.g., Ultrasound, CT, ERCP, MRC)	<input type="checkbox"/>	<input type="checkbox"/>	<input type="checkbox"/>
Alcoholic liver disease (ALD)	History, clinical and laboratory assessment (AST/ALT>2), other alcoholic disease(s)	<input type="checkbox"/>	<input type="checkbox"/>	<input type="checkbox"/>
Group II				
• Cytomegalovirus (CMV)	CMV-PCR, titer change for anti-CMV-IgM/anti-CMV-IgG	<input type="checkbox"/>	<input type="checkbox"/>	<input type="checkbox"/>
• Epstein barr virus (EBV)	EBV-PCR, titer change for anti-EBV-IgM/anti-EBV-IgG	<input type="checkbox"/>	<input type="checkbox"/>	<input type="checkbox"/>
• Herpes simplex virus (HSV)	HSV-PCR, titer change for anti-HSV-IgM/anti-HSV- IgG	<input type="checkbox"/>	<input type="checkbox"/>	<input type="checkbox"/>
• Varicella zoster virus (VZV)	VZV-PCR, titer change for anti-VZV-IgM/anti-VZV- IgG	<input type="checkbox"/>	<input type="checkbox"/>	<input type="checkbox"/>
• Other viral infections	Specific serology of HIV, Adenovirus, Coxsackie-B-Virus, Echovirus, Measles virus, Rubella virus, Flavivirus, Arenavirus, Filovirus, Parvovirus	<input type="checkbox"/>	<input type="checkbox"/>	<input type="checkbox"/>
• Other infectious diseases	Specific assessment of bacteria, fungi, parasites, worms, and others	<input type="checkbox"/>	<input type="checkbox"/>	<input type="checkbox"/>
• Autoimmune hepatitis (AIH) type I	Gamma globulins, ANA, SMA, AAA, SLA/LP, Anti-LSP, Anti-ASGPR	<input type="checkbox"/>	<input type="checkbox"/>	<input type="checkbox"/>
• Autoimmune hepatitis (AIH) type II	Gamma globulins, Anti-LKM-1 (CYP 2D6), Anti-LKM-2 (CYP 2C9), Anti-LKM-3	<input type="checkbox"/>	<input type="checkbox"/>	<input type="checkbox"/>
• Primary biliary cirrhosis (PBC)	AMA, Anti PDH-E2	<input type="checkbox"/>	<input type="checkbox"/>	<input type="checkbox"/>
• Primary sclerosing cholangitis (PSC)	p-ANCA, MRC	<input type="checkbox"/>	<input type="checkbox"/>	<input type="checkbox"/>
• Autoimmune cholangitis (AIC)	ANA, SMA	<input type="checkbox"/>	<input type="checkbox"/>	<input type="checkbox"/>
• Overlap syndromes	See AIH, PBC, PSC, and AIC	<input type="checkbox"/>	<input type="checkbox"/>	<input type="checkbox"/>
• Non alcoholic steatohepatitis (NASH)	BMI, insulin resistance, hepatomegaly, echogenicity of the liver	<input type="checkbox"/>	<input type="checkbox"/>	<input type="checkbox"/>
• Cocaine, ecstasy and other amphetamines	Toxin screening	<input type="checkbox"/>	<input type="checkbox"/>	<input type="checkbox"/>
• Rare intoxications	Toxin screening for household and occupational toxins	<input type="checkbox"/>	<input type="checkbox"/>	<input type="checkbox"/>
• Hereditary hemochromatosis	Serum ferritin, total iron-binding capacity, genotyping for C2824 and H63D mutation, hepatic iron content	<input type="checkbox"/>	<input type="checkbox"/>	<input type="checkbox"/>
• Wilson's disease	Copper excretion (24 h urine), ceruloplasmin in serum, free copper in serum, Coombs-negative hemolytic anemia, hepatic copper content, Kayser-Fleischer-ring, neurologic-psychiatric work-up, genotyping	<input type="checkbox"/>	<input type="checkbox"/>	<input type="checkbox"/>
• Porphyria	Porphobilinogen in urine, total porphyrines in urine	<input type="checkbox"/>	<input type="checkbox"/>	<input type="checkbox"/>
• α_1 – Antitrypsin deficiency	α_1 – Antitrypsin in serum	<input type="checkbox"/>	<input type="checkbox"/>	<input type="checkbox"/>
• Pancreatic diseases	Clinical and laboratory assessment, sonography, CT, MRT	<input type="checkbox"/>	<input type="checkbox"/>	<input type="checkbox"/>
• Celiac disease	TTG antibodies, endomysium antibodies, duodenal biopsy	<input type="checkbox"/>	<input type="checkbox"/>	<input type="checkbox"/>
• Anorexia nervosa	Clinical context	<input type="checkbox"/>	<input type="checkbox"/>	<input type="checkbox"/>
• Parenteral nutrition	Clinical context	<input type="checkbox"/>	<input type="checkbox"/>	<input type="checkbox"/>
• Cardiopulmonary diseases	Eg, Assessment of congestive heart disease, myocardial infarction, cardiomyopathy, cardiac valvular dysfunction, pulmonary embolism, pericardial diseases, arrhythmia, hemorrhagic shock	<input type="checkbox"/>	<input type="checkbox"/>	<input type="checkbox"/>
• Addison's disease	Plasma cortisol	<input type="checkbox"/>	<input type="checkbox"/>	<input type="checkbox"/>
• Thyroid diseases	TSH basal, T4, T3	<input type="checkbox"/>	<input type="checkbox"/>	<input type="checkbox"/>
• Grand mal seizures	Clinical context of epileptic seizure	<input type="checkbox"/>	<input type="checkbox"/>	<input type="checkbox"/>
• Heat stroke	Shock, hyperthermia	<input type="checkbox"/>	<input type="checkbox"/>	<input type="checkbox"/>
• Polytrauma	Shock, liver injury	<input type="checkbox"/>	<input type="checkbox"/>	<input type="checkbox"/>
• Systemic diseases	Liver cancer, sarcoidosis, amyloidosis, liver metastases, sepsis	<input type="checkbox"/>	<input type="checkbox"/>	<input type="checkbox"/>

This listing table, although not comprehensive, is to be used as a guide and in connection with the updated RUCAM [7], derived from a previous publication [7,8].

Abbreviations: AAA: Anti-actin antibodies; AMA: Antimitochondrial antibodies; ANA: Antinuclear antibodies; ASGPR: Asialoglycoprotein-receptor; BMI: Body mass index; CT: Computed tomography; CYP: Cytochrome P450; DPH: Pyruvate dehydrogenase; HAV: Hepatitis A virus; HBc: Hepatitis B core; HBV: Hepatitis B virus; HCV: Hepatitis C virus; HEV: Hepatitis E virus; HILI: Herb induced liver injury; HIV: Human immunodeficiency virus; LKM: Liver kidney microsomes; LP: Liver-pancreas antigen; LSP: Liver specific protein; MRC: Magnetic resonance cholangiography; MRT: Magnetic resonance tomography; p-ANCA: Perinuclear

antineutrophil cytoplasmic antibodies; PCR: Polymerase chain reaction; RUCAM: Roussel Uclaf Causality Assessment Method; SLA: Soluble liver antigen; SMA: Smooth muscle antibodies; TSH: Thyroid stimulating hormone; TTG: Tissue transglutaminase.

Causality assessment using RUCAM

Common diagnostic shortcomings in DILI include for instance the use of CAMs that are not based on a quantitative and transparent scoring system [9] such as RUCAM [7-9]. Although basically developed for idiosyncratic DILI [44,45], RUCAM has successfully been applied in intrinsic DILI caused for instance by paracetamol [33]; its use for intrinsic DILI facilitates especially the search for alternative causes [8].

RUCAM is the most used CAM for DILI worldwide [7,9], with much professional support and encouragement for its use to improve causality assessments in DILI case evaluations [59,60], as also evidenced by the large number of international RUCAM-based DILI reports published by regulatory agencies, large medical centers, registries, and authors reporting case series, case reports, epidemiological studies, and clinical trials [7]. In addition to the many reports that successfully used RUCAM as referenced [7,9], one thorough publication of DILI cases assessed by RUCAM [14] merits further attention as a report of excellence [61]. This study had been conceptualized prospectively [14], ensuring completeness of case data and high RUCAM-based causality gradings of highly probable (18%), and probable (70%), with lower gradings of possible (5%), unlikely or excluded (9%). The prospective use of RUCAM also facilitated early recognition of alternative causes in 8 patients of the study cohort: acute hepatitis E virus (HEV) in 3 patients, autoimmune hepatitis in 2 patients, and hepatitis A and B, and sarcoidosis in 1 patient each. Of note, HEV is a specific item in the updated RUCAM [7], a relevant diagnostic parameter rarely considered by other CAMs and certainly disputable if omitted because effective antiviral therapy options are available for acute HEV infections.

In more detail, RUCAM is characterized by seven well-defined and scored key elements, the sum of which provides a final score with causality grading [7]. In addition, working instructions are available in order to consider the vast majority of situations and therefore reduce inter rater variability [8]. Before assessing causality, the first step is to define a liver injury by serum activity of ALT of at least 5 x ULN and/or hepatic ALP of at least 2 x ULN [7]. The second step is to determine the type of the liver injury according to the R ratio.

The numerator is the ALT value expressed as a multiple of ULN (ALT/ ALT ULN) and the denominator the ALP value expressed also as a multiple of the ULN (ALP/ALP ULN). The ratio R should be calculated at the beginning of the liver injury as the initial type could evolve over time towards another type that would change the criteria for causality assessment. In practice, two types of liver injury are considered for evaluation: hepatocellular injury ($R > 5$) and cholestatic/mixed liver injury ($R \leq 5$) as they have different risk factors and time courses of ALT and ALP [7].

Key elements of RUCAM and their respective scores are provided for the hepatocellular injury and the cholestatic/mixed liver injury [7]. The discussion on each key element has been detailed elsewhere [7,8]. In brief, the key elements are: the timing of events, dechallenge, risk factors, comedications, search for alternative causes, known hepatotoxicity of the suspect drug and the results of rechallenge. In any case of suspected DILI it is possible to give a score to each element even when there is no information on this element (score null). The final score for each suspect drug indicates causality degrees: ≤ 0 point, excluded causality; 1-2, unlikely; 3-5, possible; 6-8, probable; ≥ 9 , highly probable. In cases of suspected drug-drug interaction, RUCAM should be applied to the suspected combination as a single product.

Individual cases of DILI due to paracetamol as examples

Compared to the large number of ALF case series that included cases of overdosed paracetamol as assumed causative agent [5,32,33,62-67], only a few reports of single cases are available dealing critically with idiosyncratic DILI by paracetamol and its related clinical diagnostic issues.

For illustration purposes, we selected cases of patients from China and Hawaii following own case evaluation using RUCAM for causality assessment.

Case from China: There is a comprehensive case from China of a woman with idiosyncratic DILI due to paracetamol use in normal dosage, with details presented as narrative (Table 3) and a probable RUCAM-based causality for paracetamol (Table 4). This case was part of a case series published earlier [12]. It may serve as an example for future cases of suspected

liver injury by paracetamol, focusing on a narrative and RUCAM based causality assessment, if the case warrants publication as a case report. However, such approach is also mandatory for any other patient under medical care.

Table 3: Narrative of a Chinese case with idiosyncratic DILI induced by paracetamol	
Narrative	
<p>A 20-year old Chinese woman living in Beijing presented to the emergency room with a history of dark brownish urine, fatigue, reduced appetite, and yellowing of her eyes and skin since 3 days. For a cold, she had been taking overall 10 tablets containing 500mg paracetamol each for a total 3 days before symptoms emerged. She denied use of alcohol, any other drug or herbal products including a dietary supplement, and other medication. There was no family history of liver disease.</p> <p>On examination, her temperature was 37.2, the pulse was 80/min, and the respiration was 18/min. The blood pressure was 120/75 mm Hg. Her BMI was 17.6kg/m² with a 160cm height and a body weight of 45kg. There was no evidence of chronic liver disease, lymphadenopathy, or Kayser-Fleischer rings. The lungs and heart were normal. The liver and spleen were not palpable. Laboratory tests showed the following results: Eosinophils 0.14 x 10⁹/L, lymphocytes 2.67 x10⁹/L, and thrombocytes 208 x 10⁹/L; ALT 1603 U/L, AST 754 U/L, TBil 228.2 umol/L, GGT 176 U/L, ALP 160 U/L, and PTA 25.9%; HBsAg, HBeAg, HBeAb, and HBcAb were all negative, HBsAb was positive; negative results were also obtained for anti-HCV, anti-HEV IgM, anti-HEV IgG, anti-HAV IgM, anti-CMV-IgM, CMV DNA, anti-EBV-IgM, EBV DNA, anti-HSV-IgM, anti-VZV-IgM, ANA, anti-SMA, AMA, anti-LKM, and anti-SLA/LP. The serum levels of α₁-antitrypsin and ceruloplasmin were normal, as was the thyroid function. A urinary test for toxic drugs was negative. An ultrasound examination of the abdomen revealed an echogenic liver and a thickening of the gallbladder wall.</p> <p>After cessation of paracetamol and NAC treatment, the liver tests improved during 30 days; ALT decreased by ≥50 % within the first 5 days. The clinical course was uneventful.</p> <p style="text-align: center;">Causality assessment: According to the updated RUCAM, her score was 8 (probable).</p> <p style="text-align: center;">Diagnosis: Idiosyncratic DILI with RUCAM-based probable causality for paracetamol at recommended daily dosage.</p>	

This Chinese case of idiosyncratic DILI by paracetamol at therapeutic dosis was included in a case series published previously [12]. Abbreviations: ALT: Alanine aminotransferase; AST: Aspartate aminotransferase; TBil: Total bilirubin; GGT: Gamma-glutamyltransferase; ALP: Alkaline phosphatase; PTA: Prothrombin activity; HBsAg: Hepatitis B surface antigen; HBeAg: hepatitis B e-antigen; HBeAb: antibody to hepatitis B e-antigen; HBcAb: Hepatitis B core antibody; HBsAb: Hepatitis B surface antibody; HCV: Hepatitis C virus; HEV: Hepatitis E virus; HAV: Hepatitis A virus; CMV: Cytomegalovirus; EBV: Epstein Barr virus; HSV: Herpes simplex virus; ANA: Antinuclear antibody; anti-SMA: Anti-smooth muscle antibody; AMA: Anti-mitochondrial antibody; anti-LKM: anti-liver-kidney microsomal antibody; anti-SLA/LP: anti-soluble liver antigen/liver pancreas antigen

Table 4: RUCAM worksheet for hepatocellular injury, applied to the Chinese patient with idiosyncratic DILI due to paracetamol.		
Suspected product: Paracetamol	Date: 5 June 2016	
Items for hepatocellular injury	Score	Result
<p>1. Time to onset from the beginning of the drug/herb</p> <ul style="list-style-type: none"> • 5 – 90 days (rechallenge: 1 – 15 days) • < 5 or > 90 days (rechallenge: > 15 days) <p>Alternative: Time to onset from cessation of the drug/herb</p> <ul style="list-style-type: none"> • ≤ 15 days (except for slowly metabolized chemicals: > 15 days) 	+2 +1 +1	 +1
<p>2. Course of ALT after cessation of the drug/herb</p> <p>Percentage difference between ALT peak and ULN</p> <ul style="list-style-type: none"> • Decrease ≥ 50 % within 8 days • Decrease ≥ 50 % within 30 days • No information or continued drug use • Decrease ≥ 50 % after the 30th day • Decrease < 50 % after the 30th day or recurrent increase 	+3 +2 0 0 -2	+3
<p>3. Risk factors</p> <ul style="list-style-type: none"> • Alcohol use (current drinks/d: > 2 for women, > 3 for men) • Alcohol use (current drinks/d: ≤ 2 for women, ≤ 3 for men) • Age ≥ 55 years • Age < 55 years 	+1 0 +1 0	 0 0

4. Concomitant drug(s)/herb(s) <ul style="list-style-type: none"> • None or no information • Concomitant drug/herb with incompatible time to onset • Concomitant drug/herb with time to onset 5-90 days • Concomitant drug/herb known as hepatotoxin and with time to onset 5-90 days • Concomitant drug/herb with evidence for its role in this case (positive rechallenge or validated test) 	0 0 -1 -2 -3	0
5. Search for alternative causes Group I (7 causes) <ul style="list-style-type: none"> • HAV: Anti-HAV-IgM • HBV: HBsAg, anti-HBc-IgM, HBV-DNA • HCV: Anti-HCV, HCV-RNA • HEV: Anti-HEV-IgM, anti-HEV-IgG, HEV-RNA • Hepatobiliary sonography / Doppler / CT / MRC • Alcoholism (AST / ALT \geq 2) • Acute recent hypotension history (particularly if underlying heart disease) Group II (5 causes) <ul style="list-style-type: none"> • Complications of underlying disease(s) such as sepsis, metastatic malignancy, autoimmune hepatitis, chronic hepatitis B or C, primary biliary cholangitis or sclerosing cholangitis, genetic liver diseases • Infection suggested by PCR and titer change for <ul style="list-style-type: none"> • CMV (anti-CMV-IgM, anti-CMV-IgG) • EBV (anti-EBV-IgM, anti-EBV-IgG) • HSV (anti-HSV-IgM, anti-HSV-IgG) • VZV (anti-VZV-IgM, anti-VZV-IgG) Evaluation of groups I and II <ul style="list-style-type: none"> • All causes-groups I and II – reasonably ruled out • The 7 causes of group I ruled out • 6 or 5 causes of group I ruled out • Less than 5 causes of group I ruled out • Alternative cause highly probable 	Tick if negative ✓ ✓ ✓ ✓ ✓ ✓ ✓ ✓ ✓ ✓ ✓ ✓ Score +2 +1 0 -2 -3	Tick if not done <input type="checkbox"/> <input type="checkbox"/> <input type="checkbox"/> <input type="checkbox"/> <input type="checkbox"/> <input type="checkbox"/> <input type="checkbox"/> <input type="checkbox"/> <input type="checkbox"/> <input type="checkbox"/> <input type="checkbox"/> <input type="checkbox"/> Result +2
6. Previous hepatotoxicity of the drug/herb <ul style="list-style-type: none"> • Reaction labelled in the product characteristics • Reaction published but unlabelled • Reaction unknown 	+2 +1 0	+2
7. Response to unintentional reexposure <ul style="list-style-type: none"> • Doubling of ALT with the drug/herb alone, provided ALT <5 x ULN before reexposure • Doubling of ALT with the drug(s)/herb(s) already given at the time of first reaction • Increase of ALT but less than ULN in the same conditions as for the first administration • Other situations 	+3 +1 -2 0	0
Total RUCAM score		8

This Chinese case of idiosyncratic DILI by paracetamol at therapeutic dose was included in a case series published previously [12]. The respective case narrative is presented (Table 3). The above items specifically refer to the hepatocellular injury rather than to the cholestatic or mixed liver injury, adapted from a previous detailed report of the updated RUCAM [7].

Abbreviations: ALT: Alanine aminotransferase; AST: Aspartate aminotransferase; CMV: Cytomegalovirus; CT: Computer tomography; DILI: Drug induced liver injury; EBV: Epstein barr virus; HAV: Hepatitis A virus; HBc: Hepatitis B core; HBsAg: Hepatitis B surface antigen; HBV: Hepatitis B virus; HCV: Hepatitis C virus; HEV: Hepatitis E virus; HSV: Herpes simplex virus; MRC: Magnetic resonance cholangiography; RUCAM: Roussel uclaf causality assessment method; ULN: Upper limit of the normal range; VZV: Varicella zoster virus. Total score and resulting causality grading: \leq 0: excluded; 1-2: unlikely; 3-5: possible; 6-8: probable; \geq 9: highly probable.

Cases from Hawaii: Admittedly, in hectic clinical settings it seems difficult to precisely document case details of patients with liver injury and prior use of paracetamol, other drugs and dietary supplements. Cases lacking such accurate evaluation should not be published as case reports, as discussed in detail [42,43,46,47]. Related to paracetamol, a specific dilemma emerged in Hawaii. In a cohort of liver patients from Honolulu

with obesity and morbid obesity. Comedication with paracetamol was documented in the re-evaluated hospital records of 6 out of 8 patients (75%) but clinically not considered as potential cause of liver injury whereas in 2 other patients there was either lack of any case details or the quality of information was insufficient [42,43]. Missing the diagnosis of liver injury by paracetamol is crucial because patients do not

receive the effective antidote therapy of NAC (N-acetylcysteine) and may run the risk of a principally not necessary liver transplantation.

One of the Honolulu patients with an alcohol problem had used Percocet (acetaminophen-oxycodone) and Vicodin (acetaminophen-hydrocodone), but hospital case records were of such low quality that valid causality assessment for paracetamol was impaired; no treatment by NAC was initiated for acetaminophen (case 1) [42]. The second patient, who had a PMH of vertical gastric sleeve/ gastric bypass operation, used Tylenol (acetaminophen), and despite poor case documentation he obtained a RUCAM based probable causality for paracetamol. The pathologist's report of the liver histology noted that consideration of acetaminophen toxicity is warranted, given the patient's gastric bypass operation, mentioned as risk factor for such toxicity; however, clinical diagnosis did not include liver injury by acetaminophen and specific treatment using NAC was not started (case 2) [42]. In the clinical records of the third patient, the use of 50 tablets tramadol-acetaminophen without details of daily dosage and duration was documented, but this information was not transferred to and available in the respective case report. Due to poor case data quality evaluation was challenging, but a RUCAM-based possible causality was obtained; since liver injury by paracetamol was clinically not considered, NAC therapy was withheld (case 3) [42]. In the next patient, the files revealed poorly documented details and the prior use of Vicodine (acetaminophen-hydrocodone), but specific therapy by NAC was not initiated; due to limited data RUCAM-based causality was excluded for paracetamol (case 4) [42]. Documented for the fifth patient was an unspecified pain syndrome, hydromorphone injection as needed for pain, but an oral medication like with paracetamol was not documented as basic therapy (case 5) [43]. No raw data were available in the sixth patient (case 6) [43]. A chronic multipain syndrome was documented in the seventh patient, who was on multiple drugs including Tylenol (acetaminophen) but respective details were not presented that would have allowed a RUCAM-based assessment of causality for paracetamol; however, documented is an initial treatment by NAC but indication for NAC use was not documented, leaving the question whether liver injury caused by paracetamol was clinically assumed (case 7) [43].

The last patient of the cohort had a chronic multipain syndrome, with documented use of multiple drugs including hydrocodone-acetaminophen, but lack of details prevented a valid RUCAM-based assessment of causality for acetaminophen (case 8) [43]. From these few cases as examples the conclusion may be warranted that patients with liver injury and preceding use of paracetamol require professional attention to ensure the correct diagnosis and facilitate consideration of NAC use as antidote.

Therapy and prognosis

Therapeutic modalities: There is some discussion about the primary elimination of paracetamol ingested in overdose of typically 15g or more [33], especially how best to remove it from the gastrointestinal tract using for instance activated charcoal; however, evidence of valid efficacy due to this potential approach is limited, even if initiated within 4 hours after the acute paracetamol ingestion [1,68]. Gastrointestinal lavage like in other intoxications by ingested toxins such as aliphatic halogenated hydrocarbons with carbon tetrachloride as example could be an alternative but may require endotracheal intubation to prevent complications by aspiration [54-56]. Problematic is also forced self-induced vomiting or medically induced emesis by ipecacuanha [1]. For none of these approaches, clear criteria of indications are available, but respective risks are known [68-70]. To establish the preferred therapeutic approach via a randomized clinical trial will be challenging because of the expected inhomogeneity of the study cohort, considering variations of the amount of paracetamol ingested, quantification of paracetamol vomited shortly after ingestion, time lag between ingestion, and start of therapy.

According to present knowledge based on the pioneering work of Mitchell et al. and Presscott [71-73], and in line with mainstream opinion [1,33,54-56,68,70], the therapy of choice for patients intoxicated by paracetamol taken in overdose is the application of the antidote NAC, available as intravenous or oral regimen (Table 5). Both methods are likely equally effective [1], and each of them has advantages as well as shortcomings [73,74]. The intravenous approach is preferred in the US [72] and in patients, who ingested a large amount of paracetamol or experience vomiting, but this treatment is conflicted by anaphylactic reactions, pruritus, flushing, urticarial

and vomiting [72]. Instead, the oral NAC regimen that is more frequently used in Europe [72] is commonly well tolerated,

whereby NAC may be applied by a nasogastric tube if vomiting is a problem.

Table 5: Treatment details using N-Acetylcysteine as antidote for intrinsic and idiosyncratic DILI by paracetamol.	
Intravenous regimen	
15 minutes in 200 mL 5% glucose solution i.v.	150mg/kg body weight
4 hours in 500 mL 5% glucose solution i.v.	50mg/kg body weight
16 hours in 1000 mL 5% glucose solution i.v.	100mg/kg body weight
Oral regimen	
Duration of therapy	N-Acetylcysteine dose
Loading	150mg/kg body weight
Every 4 hours until a total of 18 doses is reached.	70mg/kg body weight every 4 hours

Additional details are reported in several publications [1,2,33,56-58,70-74].

NAC administration aims at restoration of the hepatic glutathione content, which is decreased in the course of hepatic metabolism of paracetamol (Figure 5), whereas this reduced hepatic level may be exaggerated in malnourished patients with alcoholic liver disease or a history of alcohol abuse [1]. It seems that the reduced glutathione level in the liver is a crucial, but clinically not measurable parameter especially in alcoholic patients intoxicated by paracetamol. The indications for NAC in DILI and ALF due to paracetamol have variably been presented in several publications [1,33,54-56,68,72]. For practical reasons and a quick overview facilitating a case by case decision, a listing is provided that includes commonly accepted clinical indications [1]:

- (1) Severe paracetamol toxicity with serum ALT and/or AST >1000 U/L
- (2) Initiation of NAC within 24 hours of ingestion
- (3) Serum paracetamol levels from 140 µg/L at 4 hours to 50 µg/L at 10 hours
- (4) Acute poisoning (ingestion within 1 hour) with no other products containing acetaminophen in the past 24 hours
- (5) Acute poisoning with no ingestion of sustained release formulations
- (6) Normal ALT, AST and INR at baseline
- (7) Used ideally within the first 8-10 hours
- (8) Empirical use if paracetamol levels cannot be obtained within 8 hours of ingestion or when details of paracetamol use are suggestive but vague.

We also propose a new, additional treatment using cimetidine, targeting the metabolism of paracetamol at the site of CYP 2E1 [1,2]. It will prevent or reduce the generation of toxic intermediates through a therapeutic drug-drug interaction, likely via a mechanism involving competitive inhibition. In praxis: intravenous cimetidine should be given as bolus (200mg), and then 1600mg for the initial 24 hours via infusion pump and for the subsequent days. This regimen is commonly applied in patients with acute intoxications by carbon tetrachloride, which is also metabolized by CYP 2E1 [54-56]. Cimetidine reduces lethality and exerts hepatoprotective properties in animals intoxicated by carbon tetrachloride [73] and paracetamol [74]. Because cimetidine will readily be available, it can be used for intravenous application shortly after paracetamol ingestion at first contact with a physician. Experimentally, cimetidine and NAC work synergistically in reducing liver injury by paracetamol, likely due to differences in therapeutic targets, cimetidine for CYP 2E1 and NAC for hepatic glutathione [74].

At least in patients intoxicated by carbon tetrachloride, intravenous 400g glucose/24 hours and on subsequent days is given for down regulating microsomal functions [54-56], in analogy to the high amounts of glucose given to patients with

acute intermittent porphyria [75]. This allows down regulation of the hepatic δ -Aminolevulinic acid (ALA) synthase activity, helps reduce ALA synthesis, and impairs the synthesis of heme essential for the hemoprotein CYP [76-78], potentially an additional option for paracetamol intoxications. Finally also herbal products may ameliorate experimental liver injury by paracetamol through competing for CYP 2E1.

Outcome: Acute liver failure is a frequent complication in patients with intrinsic DILI due to paracetamol [5,30,32,33,62,72] but NAC reduced the lethality from 5% to 0.7% [1]. Patients at risk are those who have an alcohol problem, ingested large amounts of paracetamol, or received the antidote treatment delayed after acute ingestion [1,5,30,32,33,62-72]. In 42% among 662 ALF patients, paracetamol was the cause with a survival rate of 65%, a lethality rate without liver transplantation of 27%, and liver transplantation in 8% [62]. A large fraction of ALF is causally indetermined, a serious clinical problem [5,64,65,67], best to be solved prospectively by using the updated RUCAM [7].

EXPERIMENTAL ASPECTS OF PARACETAMOL, ALCOHOL AND LIVER INJURY

An exact risk profile of ethanol abuse for acute intrinsic liver injury by overdosed paracetamol is not available in humans [1,72,78-80], but experimental studies may help quantify the risk because drugs causing intrinsic DILI in humans can well be applied in animals in order to reproduce human liver injury [11]. Therefore, rats were pair-fed nutritionally adequate liquid diets containing either ethanol as 36% of total calories or isocaloric carbohydrates as controls for 4 weeks [81]. Compared to controls, chronic alcohol consumption led to slightly increased serum activities of AST, ALT, and GDH, with data shown for AST (Figure 7) and ALT (Figure 8). Paracetamol administered 18 hours after alcohol withdrawal resulted within 18 hours in a significant increase of these parameters in rats fed alcohol chronically compared to their pair-fed controls, most pronounced at the highest paracetamol dosage of 1200mg/kg body weight (Figures 7 and 8). Transferring these experimental data [81] and as confirmed subsequently [82] to humans, evidence is provided that chronic alcohol use predisposes to increased hepatotoxicity by paracetamol preferentially at high dosages.

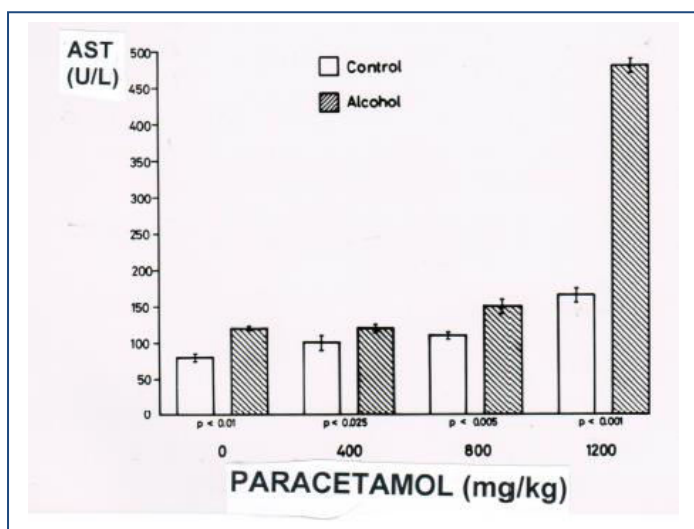


Figure 7: Effect of an acute dose of paracetamol on serum AST activities in animals pretreated for 4 weeks with a control diet as compared to an alcohol containing diet. Details are described in a previous report [82], from which this figure is reproduced with permission of the Publisher Elsevier (Amsterdam, The Netherlands).

AST: Aspartate aminotransferase

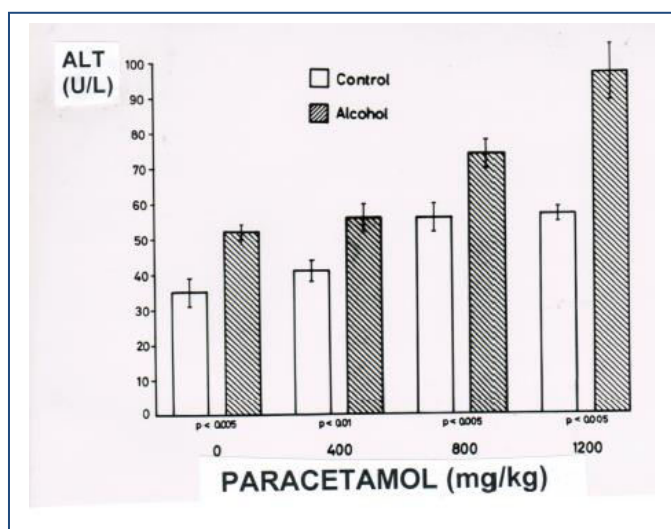


Figure 8: Effect of an acute dose of paracetamol on serum ALT activities in animals pretreated for 4 weeks with a control diet as compared to an alcohol containing diet. Data are derived and the figure is reproduced from a previous report [82] with permission of the Publisher Elsevier (Amsterdam, The Netherlands).

ALT: Alanine aminotransferase.

CONCLUSIONS

Paracetamol is worldwide consumed in large amounts. The high appreciation of this drug is due to its assumed analgesic and antipyretic properties, although a Cochrane analysis clearly summarizes concerning paracetamol: widely used and largely ineffective. Patients ingesting paracetamol in overdose are at risk developing ALF due to intrinsic drug induced liver injury. The individual risk is increased in patients with an alcohol problem, preexisting alcoholic liver disease, late antidote administration, and also likely in patients with overweight or obesity and associated NAFLD or NASH. In a similar way as with chronic alcohol use, NAFLD and NASH upregulate the hepatic microsomal CYP 2E1, the CYP isoform that plays a critical role for the microsomal metabolism of paracetamol and alcohol. Whenever paracetamol use is clinically suspected, future efforts should be directed to improve case documentation including product identification, duration of use, daily dose, and assessment of causality for paracetamol using the updated version of RUCAM. Available biomarkers are useful to verify that paracetamol was ingested, but they do not allow implicating this drug as cause or excluding alternative causes.

REFERENCES

1. Yoon E, Babar A, Choudhary M, Kutner M, Pysopoulos N. (2016). Acetaminophen-induced hepatotoxicity: a comprehensive update. *J Clin Translat Hepatol.* 4: 131-142.
2. Ramachandran A, Jaeschke H. (2018). Acetaminophen toxicity: novel insights into mechanisms and future perspectives. *Gene Expr.* 18: 19-30.
3. Moore A. (2016). Paracetamol: widely used and largely ineffective. *Cochrane.*
4. Zion Market Research Store: Global Acetaminophen (Paracetamol) Market Set for Rapid Growth, To Reach Around USD 999.4 Million by 2020.
5. Lee WM. (2017). Acetaminophen (APAP) hepatotoxicity- isn't it time for APAP to go away? *J Hepatol.* 67: 1324-1331.
6. Aithal GP, Watkins PB, Andrade RJ, Larrey D, Molokhia M, et al. (2011). Case definition and phenotype standardization in drug-induced liver injury. *Clin Pharmacol Ther.* 89: 806-815.
7. Danan G, Teschke R. (2016). RUCAM in drug and herb induced liver injury: The update. *Int J Mol Sci.* 17: 14.
8. Danan G, Teschke R. (2018). R. Drug-induced liver injury: Why is the Roussel Uclaf Causality Assessment Method (RUCAM) still used 25 years after its launch?. *Drug Saf.* 41: 735-743.
9. Teschke R, Danan G. (2018). Causality assessment methods in drug-induced liver injury. In: *Drug-induced Liver Toxicity (Chapter 27)*. Editors: Minjun Chen and Yvonne Will. Series: *Methods in Pharmacology and Toxicology/Y.* James Kang & David C. Casey. Springer Protocols, Springer Nature, Berlin Germany. 555-594.
10. Teschke R, Danan G. (2016). Diagnosis and management of drug-induced liver injury (DILI) in patients with pre-existing liver disease. *Drug Saf.* 39: 729-744.
11. Teschke R, Danan G. (2018). Drug induced liver injury with analysis of alternative causes as confounding variables. *Br J Clin Pharmacol.* 84: 1467-1477.
12. Zhu Y, Niu M, Chen J, Zou ZS, Ma ZJ, et al. (2016). Hepatobiliary and pancreatic: Comparison between Chinese herbal medicine and Western medicine-induced liver injury of 1985 patients. *J Gastroenterol Hepatol.* 31: 1476-1482.
13. Teschke R, Danan G. (2017). Drug-induced liver injury: Is chronic liver disease a risk factor and a clinical issue?. *Expert Opin Drug Metab Toxicol.* 13: 425-438.
14. Rathi C, Pipaliya N, Patel R, Ingle M, Phadke A, et al. (2017). Drug induced liver injury at a tertiary hospital in India: Etiology, clinical features and predictors of mortality. *Ann Hepatol.* 16: 442-450.
15. Andrade RJ, Lucena MI, Fernández MC, Pelaez G, Pachkoria K, et al. (2005). Drug-induced liver injury: an analysis of 461 incidences submitted to the Spanish registry over a 10-year period. *Gastroenterology.* 129: 512-521.
16. Björnsson ES, Bergmann OM, Björnsson HK, Kvaran RB, Olafsson S. (2013). Incidence, presentation, and outcomes in patients with drug-induced liver injury in the general population of Iceland. *Gastroenterology.* 144: 1419-1425.

17. Iorga A, Dara L, Kaplowitz N. (2017). Drug-induced liver injury: cascade of events leading to cell death, apoptosis or necrosis. In: Special Issue. Molecular Research on Drug Induced Liver Injury. R Teschke and G Danan. Editors. *Int J Mol Sci.* 18: 1018.
18. Jing J, Teschke R. (2018). Traditional Chinese medicine (TCM) and herb induced liver injury: comparison with drug induced liver injury. *J Clin Transl Hepatol.* 6: 57-68.
19. Teschke R. (2018). Alcoholic steatohepatitis (ASH) and acute alcoholic hepatitis (AH): Cascade of events, clinical features, and pharmacotherapy options. *Expert Opin Pharmacother.* 19: 779-793.
20. Teschke R, Ohnishi K, Hasumura Y, Lieber CS. (1977). Hepatic microsomal ethanol oxidizing system: Isolation and reconstitution. In: *Microsomes and Drug Oxidations*, editors V Ullrich I, Roots A, Hildebrandt, R.W. Estabrook, A.H. Conney. Pergamon Press, Oxford. 103-110.
21. Teschke R, Matsuzaki S, Ohnishi K, DeCarli LM, Lieber CS. (1977). Microsomal ethanol oxidizing system (MEOS): Current status of its characterization and its role. *Alcohol Clin Exp Res.* 1: 7-15.
22. Lieber CS, De Carli LM, Feinman L, Hasumura Y, Korsten M, et al. (1975). Effect of chronic alcohol consumption on ethanol and acetaldehyde metabolism. In: *Alcohol Intoxication and Withdrawal: Experimental Studies II*. Gross MM, editors. *Advances in Experimental Medicine and Biology*. Plenum Press. 59: 185-227.
23. Teschke R, Hasumura Y, Joly JG, Ishii H, Lieber CS. (1972). Microsomal ethanol-oxidizing system (MEOS): Purification and properties of a rat liver system free of catalase and alcohol dehydrogenase. *Biochem Biophys Res Commun.* 49: 1187-1193.
24. Teschke R, Gellert J. (1986). Hepatic microsomal ethanol-oxidizing system (MEOS): Metabolic aspects and clinical implications. *Alcohol Clin Exp Res. Suppl.* 10: 20S-32S.
25. Shaw S, Rubin KP, Lieber CS. (1983). Depressed hepatic glutathione and increased diene conjugates in alcoholic liver disease. *Dig Dis Sci.* 28: 585-589.
26. TOXNET. Phenacetin.
27. Teschke R, Schulze J, Eickhoff A, Danan G. (2017). Drug induced liver injury: Can biomarkers assist RUCAM in causality assessment? Special issue: Molecular Research on Drug Induced Liver Injury. *Int J Mol Sci.* 18: 803.
28. Roberts DW, Lee WM, Hinson JA, Bai S, Swearingen CJ, et al. (2017). An immunoassay to rapidly measure acetaminophen protein adducts accurately identifies patients with acute liver injury or failure. *Clin Gastroenterol Hepatol.* 15: 555-562.
29. Heard K, Anderson V, Dart RC, Kile D, Lavonas EJ, et al. (2017). Serum acetaminophen Protein Adduct Concentrations in pediatric Emergency Department patients. *J Pediatr Gastroenterol Nutr.* 64: 533-535.
30. Wong A, Graudins A. (2017). Risk prediction of hepatotoxicity in paracetamol poisoning. *Clin Toxicol (Phila).* 55: 879-892.
31. Heard K, Anderson V, Lavonas E, Dart RC, Green JL. (2018). Serum paracetamol-protein adduct concentrations in ambulatory subjects: relationship to recent reported paracetamol use. *Biomarkers.* 23: 288-292.
32. Watkins PB, Kaplowitz N, Slattery JT, Colonese CR, Colucci SV, et al. (2006). Aminotransferase elevations in healthy adults receiving 4 grams of acetaminophen daily: a randomized controlled trial. *JAMA.* 296: 87-93.
33. Sabaté M, Ibáñez L, Pérez E, Vidal X, Buti M, et al. (2011). Paracetamol in therapeutic dosages and acute liver injury: causality assessment in a prospective case series. *BMC Gastroenterol.* 11: 80.
34. Lieber CS, DeCarli LM. (1970). Hepatic microsomal ethanol-oxidizing system. In vitro characteristics and adaptive properties in vivo. *J BiolChem.* 245: 2505-2512.
35. Teschke R, Moreno F, Petrides AS. (1981). Hepatic microsomal ethanol-oxidizing system (MEOS): respective roles of ethanol and carbohydrates for the enhanced activity after chronic alcohol consumption. *Biochem Pharmacol.* 30: 1745-1751.
36. Koop DR, Casazza JP. (1985). Identification of ethanol-inducible P-450 enzyme 3a as the acetone and acetol monooxygenase of rabbit microsomes. *J Biol Chem.* 260: 13607-13612.
37. Johansson IJ, Eliasson E, Norsten C, Ingelman-Sundberg M. (1986). Hydroxylation of acetone by ethanol- and acetone-inducible cytochrome P-450 in liver microsomes and reconstituted membranes *FEBS Lett.* 196: 59-64.

38. Salazar DE, Sorge CL, Cocoran GB. (1988). Obesity as a risk factor for drug-induced organ injury. VI. Increased hepatic P450 concentration and microsomal ethanol oxidizing activity in the obese overfed rat. *Biochem Biophys Res Commun.* 157: 315-320.
39. Yoo J, Ning SM, Pantuck CB, Pantuck EJ, Yang CS. (1991). Regulation of hepatic microsomal cytochrome P-450 2E1 level by dietary lipids and carbohydrates in rats. *J Nutr.* 121: 959-965.
40. Raucy JL, Lasker JM, Kramer JC, Salazer DE, Lieber CS, et al. (1991). Induction of cytochrome P450IIE1 in the obese overfed rat. *Mol Pharmacol.* 39: 275-280.
41. Koop DR. (1992). Oxidative and reductive metabolism by cytochrome P-450 2E1. *FASEB J.* 6: 724-730.
42. Teschke R, Schwarzenboeck A, Frenzel C, Schulze J, Eickhoff A, et al. (2016). The mystery of the Hawaii liver disease cluster in summer 2013: A pragmatic and clinical approach to solve the problem. *Annals of Hepatology.* 15: 91-109.
43. Teschke R, Eickhoff A. (2016). The Honolulu Liver disease cluster at the Medical Center: Its mysteries and challenges. *Int J Mol Sci.* 17: 476.
44. Danan G, Bénichou C. (1993). Causality assessment of adverse reactions to drugs – I. A novel method based on the conclusions of international consensus meetings: application to drug-induced liver injuries. *J Clin Epidemiol.* 46: 1323-1330.
45. Bénichou C, Danan G, Flahault A. (1993). Causality assessment of adverse reactions to drugs – II. An original model for validation of drug causality assessment methods: case reports with positive rechallenge. *J Clin Epidemiol.* 46: 1331-1336.
46. Teschke R, Schulze J, Eickhoff A, Wolff A, Frenzel C. (2015). Mysterious Hawaii liver disease case – Naproxen overdose as cause rather than OxyELITE Pro? *J Liver Clin Res.* 2: 1013.
47. Teschke R, Eickhoff A. (2017). Suspected liver injury and the dilemma of causality. *Dig Dis Sci.* 62: 1095-1098.
48. Teschke R, Eickhoff A, Wolff A, Xuan TD. (2018). Liver injury from herbs and “dietary supplements”: Highlights of a literature review from 2015 to 2017. *Curr Pharmacol Rep.* 4: 120-131.
49. Teschke R, Xuan TD. (2018). Viewpoint: A contributory role of Shell ginger (*Alpinia zerumbet*) for human longevity of Okinawa in Japan? *Nutrients.* 10: 166.
50. Teschke R, Wolff A, Eickhoff A, Danan G. (2018). Is obesity rather than the dietary supplement used for weight reduction the cause of liver injury? *J Gastroenterol Hepatol Open.* 2: 152-157.
51. Sattar N, Forrest E, Preiss D. (2014). Non-alcoholic fatty liver disease. *BMJ.* 349: 4596.
52. Lieber CS. (1997). Cytochrome P-4502E1: its physiological and pathological role. *Physiol Rev.* 77: 517-544.
53. Tanaka E, Terada M, Misawa S. (2000). Cytochrome P450 2E1: its clinical and toxicological role. *Clin Pharm Ther.* 25: 165-175.
54. Teschke R. (2018). Liver injury by carbon tetrachloride intoxication in 16 patients treated with forced ventilation to accelerate toxin removal via the lungs: A clinical report. *Toxics.* 6: 25.
55. Teschke R. (2018). Intoxications by aliphatic halogenated hydrocarbons: hepatotoxic risks for patients and clinical issues including role of CO₂-induced hyperventilation as therapy option. *J Clin Exp Tox.* 2: 20-24.
56. Teschke R. (2018). Aliphatic halogenated hydrocarbons: Liver injury in 60 patients. *J Clin Translat Hepatol.* 6: 350-361.
57. Hasumura Y, Teschke R, Lieber CS. (1974). Increased carbon tetrachloride hepatotoxicity, and its mechanism, after chronic ethanol consumption. *Gastroenterology.* 66: 415-422.
58. Björnsson ES. (2016). Hepatotoxicity by drugs: the most common implicated agents. *Int J Mol Sci.* 17: 224.
59. Sarges P, Steinberg JM, Lewis JH. (2016). Drug-induced liver injury: Highlights from a review of the 2015 literature. *Drug Saf.* 39: 801-821.
60. Shahbaz O, Mahajan S, Lewis JH. (2017). Highlights of drug- and herb-induced liver injury in the literature from 2016: How best to translate new information into clinical practice? *Exp Opin Drug Metab Toxicol.* 13: 935-951.
61. Teschke R, Danan G. (2017). Prospective Indian study of DILI with confirmed causality using the Roussel Uclaf Causality Assessment Method (RUCAM): A report of excellence. *Ann Hepatol.* 16: 324-325.

62. Larson AM, Polson J, Fontana RJ, Davern TJ, Lalani E, et al. (2005). Acetaminophen-induced acute liver failure: Results of a United States multicentre, prospective study. *Hepatology*. 42: 1364-1372.
63. Nourjah P, Ahmad SR, Karwoski C, Willy M. (2006). Estimates of acetaminophen (Paracetamol)-associated overdoses in the United States. *Pharmacoepidemiol Drug Saf*. 15: 398-405.
64. Bernal W, Auzinger G, Dhawan A, Wendon J. (2010). Acute liver failure. *Lancet*. 376: 190-201.
65. Khandelwal N, James LP, Sanders C, Larson AM, Lee WM, et al. (2011). Unrecognized acetaminophen toxicity as a cause of indeterminate acute liver failure. *Hepatology*. 53: 567-576.
66. Reuben A, Koch DG, Lee WM, and the Acute Liver Failure Study Group. (2010). Drug-induced acute liver failure: Results of a U.S. multicenter, prospective study. *Hepatology*. 52: 2065-2076.
67. Ganger DR, Rule J, Rakela J, Bass N, Reuben A, et al. (2018). Acute liver failure of indeterminate etiology: a comprehensive systematic approach by an expert committee to establish causality. *Am J Gastroenterol*. 113: 1319-1328.
68. Underhill TJ, Greene MK, Dove AF. (1990). A comparison of the efficacy of gastric lavage, Ipecacuanha and activated charcoal in the emergency management of paracetamol overdose. *Arch Emerg Med*. 7: 148-154.
69. Chun LJ, Tong MJ, Busuttill RW, Hiatt JR. (2009). Acetaminophen hepatotoxicity and acute liver failure. *J Clin Gastroenterol*. 43: 342-349.
70. Buckley N, Eddleston M. (2007). Paracetamol (acetaminophen) poisoning. *BMJ Clin Evid*. 2007: 2101.
71. Mitchell JR, Thorgeirsson SS, Potter WZ, Jollow DJ, Keiser H. (1974). Acetaminophen-induced hepatic injury: protective role of glutathione in man and rationale for therapy. *Clin Pharmacol Ther*. 16: 676-684.
72. Prescott L. (2005). Oral or intravenous N-Acetylcysteine for acetaminophen poisoning? *Ann Emerg Med*. 45: 409-413.
73. Homann J, Rotter S, Schneider S, Röttger P, Kratz F, et al. (1985). Influence of cimetidine on CCl₄-induced liver injury and survival in rats. *Biochem Pharmacol*. 34: 415-416.
74. Speeg KV, Mitchell MC, Maldonado AL. (1985). Additive protection of cimetidine and N-acetylcysteine treatment against acetaminophen-induced hepatic necrosis in the rat. *J Pharmacol Exp Ther*. 234: 550-554.
75. Pischik E, Kauppinen R. (2015). An update of clinical management of acute intermittent porphyria. *Appl Clin Genet*. 8: 201-214.
76. Tschudy DP, Welland FH, Collins A. (1964). The effect of carbohydrate feeding on the induction of delta-aminolevulinic acid synthetase. *Metabolism*. 13: 396-406.
77. Puy H, Deybach JC. Haem biosynthesis and excretion of porphyrins. Chapter 2.3.10. In: *Textbook of Hepatology*, 3rd edition. Juan Rodés, Jean-Pierre Benhamou, Andrés Blei, Jürg Reichen, and Mario Rizzetto (editors). eBooks, Gastro Hep.com. 207-214.
78. Levin W, Jacobson M, Kutzman R. (1972). Incorporation of radioactive-¹⁴C-aminolevulinic acid into microsomal cytochrome P 450 : selective breakdown of the hemoprotein by allylisopropylacetamide and carbon tetrachloride. *Arch Biochem Biophys*. 148: 262-269.
79. Riordan SM, Williams R. (2002). Alcohol exposure and paracetamol-induced hepatotoxicity. *Addict Biol*. 7: 191-206.
80. Manchandra A, Cameron C, Robinson G. (2013). Beware of paracetamol use in alcohol abusers: a potential cause of acute liver injury. *N Zeal Med J*. 126: 80-84.
81. Teschke R, Stutz G, Strohmeyer G. (1979). Increased paracetamol-induced hepatotoxicity after chronic alcohol consumption. *Biochem Biophys Res Commun*. 91: 368-374.
82. Sato C, Matsuda Y, Lieber CS. (1981). Increased hepatotoxicity of acetaminophen after chronic ethanol consumption in the rat. *Gastroenterology*. 80: 140-148.