

Definition of Different Treatment Response Types in Neovascular Age-Related Macular Degeneration

Ayşe Gul Kocak Altıntaş*

Sağlık Bilimleri University Ulucanlar Eye Hospital, Ankara, Turkey

ARTICLE INFO

Received Date: February 25, 2022

Accepted Date: March 28, 2022

Published Date: March 31, 2022

KEYWORDS

Age-related macular degeneration

Anti-VEGF

Resistance n- AMD

Refractory n- AMD

Recalcitrant n-AMD

Tolerance

Tachyphylaxis

Pharmacodynamic

Pharmacokinetic.

Copyright: © 2022 Ayşe Gul Kocak Altıntaş. Ophthalmology And Ophthalmic Surgery. This is an open access article distributed under the Creative Commons Attribution License, which permits unrestricted use, distribution, and reproduction in any medium, provided the original work is properly cited.

Citation for this article: Ayşe Gul Kocak Altıntaş. Definition of Different Treatment Response Types in Neovascular Age-Related Macular Degeneration. Ophthalmology And Ophthalmic Surgery. 2022; 4(1):120

Corresponding author:

Ayşe Gul Kocak Altıntaş,
Sağlık Bilimleri University Ulucanlar
Eye Hospital, Ankara, Turkey, Tel:
+905327988488;
Email: aysegulkaltintas@hotmail.com

ABSTRACT

Age-related macular degeneration (AMD) is a common, degenerative disease of the retina presented as neovascular AMD (n-AMD) or non-neovascular AMD. Several factors risk factors having been found associated with unresponsive to treatment and progression macular scar form, including subtype of the Choroidal Neovascular Membrane (CNM), presence of subretinal drusenoid deposits, Pigment Epithelial Detachment (PED), decreased central choroidal thickness, pre-existing MA in the fellow eye. There is no exact consensus about the term described the status of poor or non-response to any treatment regime. In this article definition of different therapeutic responses such as resistance, refractory, recurrence of anti-vascular endothelial growth factors (Anti-VEGF), and its relation to retinal features are discussed.

INTRODUCTION

Age-Related Macular Degeneration (AMD) is a progressive, degenerative disease of the retina. World Health Organization has indicated that AMD is a common cause of worldwide visual impairments for individuals above the age of 55. Its frequency is increasing with advancing age, and the estimated global prevalence is 8.7%. The prevalence rates are higher among European people than Africans and Asians. Its frequency is as high as 50% of the population of legal blindness in some countries. The end-stage AMD is affecting more than 5% of people older than 90 years of age in Western societies [1-7].

The advanced stage of disease presented as neovascular AMD (n-AMD) (exudative or wet form) and dry AMD (the atrophic, non- exudative or non-neovascular form). Both forms can exist together in the same eye or presented with neovascular AMD in one eye and atrophic form in the fellow eye [6-8].

Vascular Endothelial Growth Factors (VEGF) play a crucial role in the development of Choroidal neovascular membrane (CNV), the hallmark of n-AMD. Nowadays, Anti-VEGF therapy is the gold standard treatment in n-AMD. If these aberrantly growing immature vascular structures do not treat, they typically leak exudates, bleeds, and finally, fibrous scar develops. In addition to VEGF, many other proangiogenic factors such as platelet-derived growth factor (PDGF) placental GF (PGF), fibroblast GF (FGF), transforming GF (TGF), interleukins, tumor necrosis factor play an essential role in the development of CNM. The increased expression of these factors during antiangiogenic monotherapy may stimulate other alternative VEGF-independent angiogenesis pathways. Therefore persistence or recurrence of fluid accumulation,

hemorrhage, retinal atrophy, or fibrosis can occur even under the regular Anti-VEGF treatment [8-12] (Figure 1a, Figure 1b).

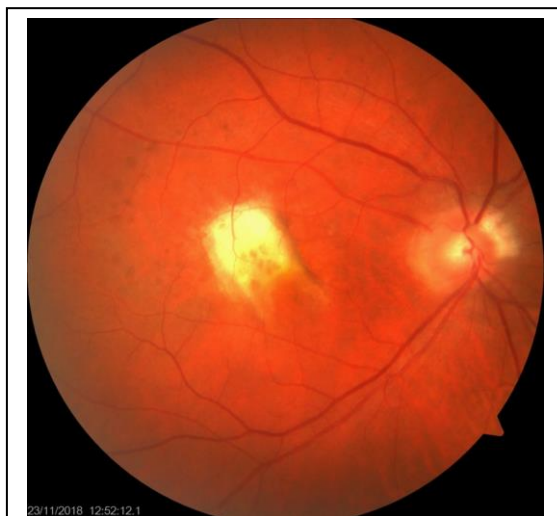

Figure 1a: Fundus photograph of Fibrous scar due to neovascular Age-related macular degeneration (n-AMD).

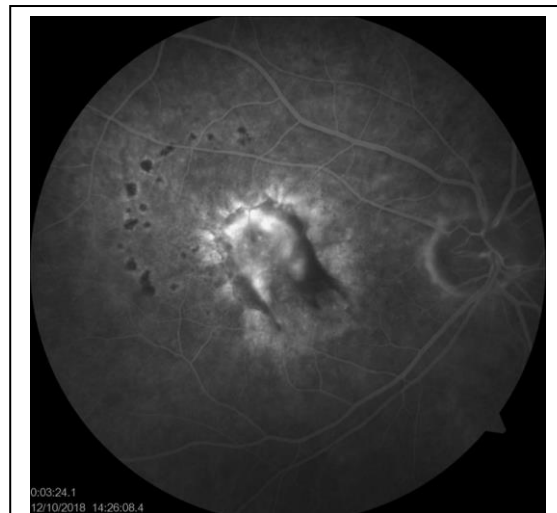

Figure 1b: Fibrous scar due to n-AMD evaluated by fluorescence angiography (FFA).

Cross-sectional follow-up studies showed the prominent enlargement of CNM associated atrophy and fibrosis within the region previously occupied by the neovascular lesions under treatment. According to the multivariate regression analysis, atrophy and fibrotic scar can occur in 2 to 7 years during the anti-VEGF treatment. The chorioretinal atrophy was found in 98% of subjects who had anti-VEGF treatment 7 or 8 years previously [6,13-16]. Zarubina et al [10]. observed macular atrophy (MA) in only 16% of eyes with treatment-naïve n-AMD. However, 51% of eyes of their patient had not MA initially developed neovascular-associated MA and fibrotic

scar with the anti-VEGF treatment during the mean follow-up of 4.7 years.

Several interindividual factors including lesion type, such as the presence of subretinal drusenoid deposits, Pigment epithelial detachment (PED), type of neovascular membrane, decreased central choroidal thickness, pre-existing MA in the fellow eye, genetic predisposition, patients metabolism having been found associated with unresponsive to anti-VEGF treatment and poor visual outcome in the long term. Furthermore, the molecular feature of Anti-VEGF such as molecular size, molecular morphology, VEGF binding affinity, their potential effect on other growth factors, treatment dose and regimes are also associated with the treatment response [6,7,9,15-17].

Definition of insufficient treatment response to Anti-VEGF agents in n-AMD

In many reports, different terms such as "refractory n- AMD," "recalcitrant n-AMD," resistance to anti-VEGF therapy," and "recurrent n-AMD" are frequently used. Even some scientific papers do not make a distinction between these terms, and there is still not a consensus regarding their definition [17-20].

Some researchers consider the refractory n- AMD and recalcitrant n- AMD" is the synonym terms. These terms define the eyes have persistence of exudation, fibrovascular pigment epithelial detachment combined with intraretinal (IR) or subretinal (SR) fluid accumulation, or increasing hemorrhage comparing to the baseline after the six consecutive Anti-VEGF injections. On the other hand, some researchers used these two terms in eyes to show partial and temporary response initially but become stationary, or increased IR or SR exudation even treated with more than three consecutive injections [18-23]. In MARINA and ANCHOR studies, more than 30% of eyes responded four months after the beginning of treatment. Therefore only three initial injections should not be considered the threshold for recalcitrating or refractory n-AMD [17,18]. Fung et al. [24] considered refractory n- AMD presented with persistent fluid on OCT at more than 30 days after the last of six monthly anti-VEGF injections. Grewal et al. [20] defined the concept of "recalcitrant n- AMD" is persistent exudation after six months of regular monthly anti-VEGF treatment.

Dosing regimes may be modified for the treatment of refractory n-AMD. Steward [25] reported the theoretical

advantage of more frequent dosing of Anti-VEGF than monthly injection in refractory n-AMD. They showed that binding activity of ranibizumab injection at every 14 days was 21.75 times higher than the every 28 days injection. They suggest that amount of residual drug from the prior injection may increase the following anti-VEGF efficacy. In contrast to their theory, Chan et al. [26] reported that the 84 eyes were refractory to ranibizumab had an average of 3 weeks interval for each injection during the six months of the treatment period. They suggested that the higher than the recommended monthly injection of ranibizumab may cause resistance to these eyes. Therefore mathematical models are not directly correlated with real-life outcomes. Horizon study, showed that ranibizumab treatment less than monthly injection might cause worse visual outcome [27]. On the other hand treat-and-extend regime with less than the monthly dosing is recommended in eyes when visual stability achieved and disappearance of macular hemorrhage and exudate on OCT [28,29].

Even there is no exact consensus about the term "resistant," it is generally described the status of a diminished therapeutic effect following an initial successful response, despite the continuous regular treatment [30,31]. Bakall et al. [31] observed that some eyes showed a good initial response with the absorption of IR or SR exudate but later on presented with recurrent exudation and became resistant to any further injection. Resistance can occur at any time during to Anti-VEGF therapy. Even the therapy may fail from the very beginning, and eyes showed inadequate response or nonresponse to the initial therapy. Tranos et al. [32] reported that 50% of the patients did not show significant improvement, and nearly 10% of the patients had no response at all despite continuous standard anti-VEGF injection. Therefore eyes had inadequate response or nonresponse to the initial therapy, or had a successful initial response, then showed a slow loss of response with persistent fluid is consider as resistant n-AMD.

Macular Degeneration Treatments Trials Research Group reported that 51.5% of eyes treated with ranibizumab and 67.4% of eyes receiving bevacizumab had persistent exudation demonstrate by optical coherence tomography (OCT) despite monthly intravitreal (IV) injection for two years [14]. Heier et al. [33] showed that 19.7%–36.6% of eyes had evidence of persistent fluid demonstrated on either fluorescein

angiography or OCT despite 4 or 8 weekly regular aflibercept injections after one year treatment period. The resistance may occur in every treatment regimes with different anti-VEGF agents. Therefore distinguish between resistance to anti-VEGF therapy” and “resistance to anti-VEGF agents” is essential because some eyes seem to be resistant may respond to different anti-VEGF agents (Figure 2a, Figure 2b).

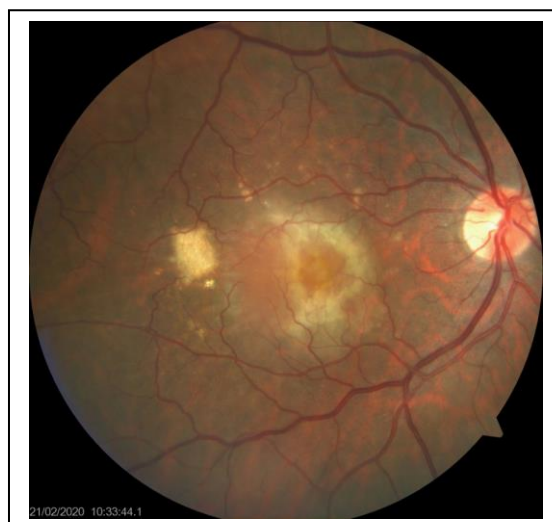

Figure 2a: Fundus photography of resistant n-AMD.

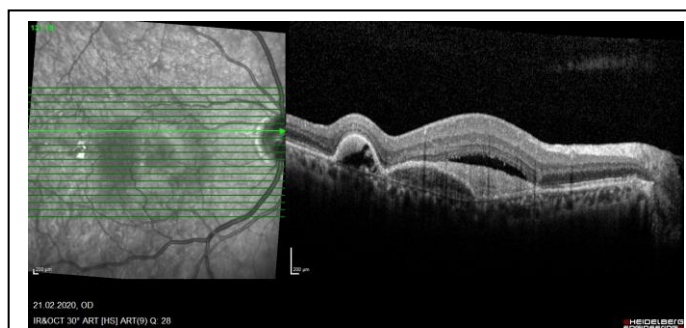


Figure 2b: Persistence of subpigmentepithelial, subretinal or intraretinal fluid accumulation in n-AMD.

Bakall et al. [31] reported that 36 eyes with recurrent or persistent exudation during the treatment of either ranibizumab or bevacizumab were converted to aflibercept. They observed the reduction of SR fluid in 50% of eyes, unchanged in 41% of eyes while increasing the exudation in only 8.3% of eyes. Chan et al. [26] observed the reduction of SR fluid in 84.3% of eyes, unchanged in 1.1% of eyes while increased in 14.6 % eyes, which are resistant to ranibizumab or bevacizumab than converted to aflibercept.

The term of recurrent” is explaining the situation that eyes have complete resolution of IR or SR exudation with continuous treatment. However, once the treatment is withdrawn, at least two recurrences of IR or SR fluid occur. [14,34]. Arcinue et al. [34] reported that if only one recurrence of fluid accumulation was observed, it could be classified as the recurrence of neovascular AMD, instead of "recurrent neovascular AMD." In eyes with recurrent n-AMD visual deterioration or other visual symptoms are also occur again. Kuroda et al. [35] observed that 65.7% of their patients had a recurrence of retinal exudates in 12 months, and 74.8% had a recurrence in 24 months.

Frequent injections are necessary for recurrent n-AMD treatment. Some eye responds well to repeated injections despite multiple recurrences, and eventually, whole exudates disappeared, and macula becomes dry or atrophic scars develop.

Regardless of the categorization of n-AMD as refractory, resistant, or recurrent Amoaku et al. [36] classified the response to anti-VEGF therapies according to both visual outcomes and morphological features as good or optimal response, poor response, and nonresponse. This incomplete effect of treatment may develop based on either tolerance or tachyphylaxis [37-40].

Tolerance and Tachyphylaxis in treatment of n-AMD

Tolerance is a pharmacological term that is a subject's response to a specific therapeutic agent, and the active physiological concentration of the agent is diminished, followed by repeated use. So that to reach the optimal effect, either increased dosage or shorter dosing time intervals are required. On the other hand, monthly dosing patients have more atrophic lesions than PRN treatment patients that have less total injections [22,25,26].

Pharmacological tolerance for Anti-VEFG could be presented with different types such as pharmacodynamic tolerance, and metabolic or pharmacokinetic tolerance [20,21,41].

Pharmacodynamic tolerance for anti-VEGF agents may cause the increment of VEGF receptors expression, which are especially located within the CMN tissue. Besides, signal transduction changes decrease in VEGF inhibition by upregulating the VEGF production. Furthermore, in this pharmacodynamic tolerance, the stimulus for CNM is changing

toward the other growth factors such as PDGF, PGF, FGF [22,34,38,41].

Pharmacokinetic or metabolic tolerance occurs due to decreased active substance of the drug that reaches the corresponding receptor. It may occur by the development of systemic or local immune response, the production of neutralizing antibodies, or increasing clearance from the eye [22,37,38].

Tachyphylaxis is a medical concept that suddenly developed diminish in response to medicine following given a series of adequate doses. However, most of the researchers have considered that tachyphylaxis can be developed as early as after two Anti-VEGF injections because of the mechanism of tachyphylaxis for the anti-VEGF agent in for n-AMD is still not well explained. To overcome the tachyphylaxis, treatment with the same properties should stop for a while or switch to another similar drug. Because increasing the dosage with the same drug cannot be effective in these eyes [22,37-41]. Several studies reported a good therapeutic response after switching between bevacisumab and ranibizumab. These two molecules have a similar molecular structure. Nevertheless, Ranibizumab (48-kDa molecule weight) penetrates deeper into the outer retina, RPE and choriocapillaris due to its smaller size than bevacisumab (149 kDa molecule weight) and may cause more reduction in SRF than bevacisumab in some patient. On the other hand, bevacisumab has different pharmacological distribution into the retina and penetrate the subretinal space [26,28]. Aflibercept has a wider action spectrum and higher binding capacity due to its molecule as a VEGF trap. Steward and coworkers [25] found the 2.0 mg aflibercept injection every 28 days cause 838 to 3.354-fold higher binding activity compared to 1.25 mg bevacisumab in their mathematical modeling. They also show the same amount of aflibercept injection provides 1.892 fold higher binding activity comparing to 0.5 mg ranibizumab every 28 days, and aflibercept has 84-fold higher binding activity when compared the same dosed ranibizumab injection at every 14 days.

Several diagnostic tools are available for classified the CNM and demonstrate the subtle coexisting pathologies that affect therapeutic response to Anti-VEGF and prognosis. Based on OCT features and anatomic localization of the membrane, CNM classified as type 1 CNV or vascularized Pigment

Epithelial Detachment (PED), type 2, and type 3 CNV or retinal angiomatous proliferation (RAP). Type 1 CNV, vascularized PED, seen more frequently than type 2 CNV in and are known to be more challenging to treat, and became refractory to treatment with Anti-VEGF [8,11,40-42].

Fibrovascular pigment epithelial detachment in type 1 CNM causes a significant separation and blockage of the RPE from the choriocapillaris that reduces oxygen and nutrient transport to the RPE. RPE and subsequently, photoreceptors ischemia may occur due to the "steal" phenomenon that blood flow diverts to recently developed pathologic blood vessels in the choroidal membrane instead of choriocapillaris [9-12,41-43].

RAP, which is also known as type 3 CNV, according to anatomic classifications, occurs 10%–12% of newly diagnosed n-AMD lesions. RAP may have similar feature types 1 and 2 CNV on fundus fluorescence angiography (FFA). However, OCT angiography (OCTA), which evaluates the retinal microvasculature based on motion contrast imaging, plays an important role in the correct early diagnosis of RAP [15,44-47]. Even RAP is classified as a CNM, it differs them with the natural course and has poorer visual improvement under anti-VEGF monotherapy. Even in a subanalysis of the CATT study, RAP lesions showed an optimal response to anti-VEGF therapy, it is recommended to apply Photodynamic Dynamic Treatment (PDT) combination with Anti-VEGF injection to achieve optimal response [15,47].

Polypoidal choroidal vasculopathy (PCV) is a predominant variant of n-AMD in Asian populations, may misdiagnose as a classical CNVs. PCV may appear as a CNV on fundus photography and FFA. On the other hand, on the early-phase of Indocyanine Green Angiography (ICG) focal hyperfluorescent, the "hot" spots under the RPE of polyps are the gold standard for diagnosis for PCV. PCV occurs as high as 22.3%–61.6% of cases in Asian populations and only 8%–13% of Western populations. Therefore ICG becomes nearly as a routine examination in Asian countries. Anti-VEGF monotherapy with either ranibizumab or bevacizumab is less effective in PCV than in other types of CNVs. A combination of anti-VEGF/PDT therapy or aflibercept, as a VEGF trap drug are more effective to improve visual acuity and macular lesions morphology in eyes with PCV [23,48-52].

Subretinal drusenoid deposits referred to as reticular pseudodrusen (RPD) by their reticular images on OCT, correlated with the atrophic scar. RPD may cause outer retinal ischemia, loss of RPE, and choriocapillaris. They may also be able to disrupt metabolic pathways essential for photoreceptor and RPE survival. Zarubina et al. [10] reported that the presence of RPD causes 3 to 6.5 - fold increased the risk of MA development during the Anti-VEGF treatment. The risk of MA is independent of other risk factors, including intraretinal neovascularization or thin choroid. RPD presented with two different forms as 'dots' and 'ribbons' on OCT images. The ribbon phenotype biomarker is correlated with MA while dot phenotype is correlated with n-AMD [10,53,54].

AMD is influenced by genetic factors for both response to treatment and progression to advanced AMD. Numerous genetic variants may cause higher inflammation levels that affect the membrane progression, and resistance to anti-VEGF therapy may lead to a frequent recurrence of neovascularization [2,6,7,50].

Several structural lesions, such as outer retinal tubulations and chronic intraretinal cysts, have a similar feature as leakage on OCT. These findings are accepted as permanent markers of atrophy that should not be considered as anti-VEGF treatment resistance n-AMD [45,55].

Alternative medical treatment choice is developing, such as Conbercept and Fovista. Conbercept is a novel VEGF inhibitor with similar molecular integrity to that of Aflibercept. It is an also recombinant fusion protein with the ligand-binding part of VEGF receptors [56]. Fovista is a recently developing a PDGF antagonist. Anti-VEGF agents only distract the endothelial cells but not pericytes of neovascular membrane. After the standard Anti-VEGF treatment, empty vascular channels formed by pericyts left behind and served as a sleeve for endothelial cells repopulation. Combine treatment with Anti-VEGF and Fovista is expecting to reach better treatment results in eyes with poor treatment response [22,57].

As a conclusion n-AMD is a complicated disease that has multiple pathogenic pathways. The patient should be re-examine with the different diagnostic tools to evaluate the biomarkers and for correct diagnosis. Different anti-VEGF agents have different VEGF binding efficacy and different spectrum of action. Dynamic adjustment of dosage and

treatment intervals, as well as choose in medical alternatives, are essential to achieve optimal treatment outcomes. Further researches will help to explain both the pathophysiology of AMD and developing new treatment alternatives.

REFERENCES

- Song P, Du Y, Kit Yee, Chan KY, Theodoratou E, et al. (2017). The National and Subnational Prevalence and Burden of Age-Related Macular Degeneration in China. *J Glob Health*. 7: 020703.
- Klein R, Chou CF, Klein BE, Zhang X, Meuer SM, et al. (2011). Prevalence of age-related macular degeneration in the US population. *Arch Ophthalmol*. 129: 75–80.
- Gunnlaugsdottir E, Arnarsson A, Jonasson F. (2008). Prevalence and causes of visual impairment and blindness in Icelanders aged 50 years and older: the Reykjavik Eye Study. *Acta Ophthalmol*. 86: 778–785.
- Wong WL, Su X, Li X, Cheung CM, Klein R, et al. (2014). Global prevalence of age-related macular degeneration and disease burden projection for 2020 and 2040: a systematic review and meta-analysis. *Lancet Glob Health*. 2: e106–116.
- Rees A, Zekite A, Bunce C, Patel PJ. (2014). How many people in England and Wales are registered partially sighted or blind because of age-related macular degeneration? *Eye (Lond)*. 28: 832–837.
- (2008). Complications of Age-related Macular Degeneration Prevention Trial (CAPT) Research Group. Risk factors for choroidal neovascularization and geographic atrophy in the Complications of Age-Related Macular Degeneration Prevention Trial. *Ophthalmology*. 115: 1474–1479.
- Bird AC, Phillips RL, Hageman GS. (2014). Geographic atrophy: a histopathological assessment. *JAMA Ophthalmol*. 132: 338–345.
- Ferris FL, Wilkinson CP, Bird A, Chakravarthy U, Chew E, et al. (2013). Clinical classification of age-related macular degeneration. *Ophthalmology*. 120: 844–851.
- Tan AC, Dansingani KK, Yannuzzi LA, Sarraf D, Freund KB. (2016). Type 3 neovascularization imaged with cross-sectional and en face optical coherence tomography angiography. *Retina*. 37: 234–246.
- Zarubna AV, Gal-Or O, Huisingh CE. (2017). Macular Atrophy Development and Subretinal Drusenoid Deposits in Anti-Vascular Endothelial Growth Factor Treated Age-Related Macular Degeneration Invest *Ophthalmol Vis Sci*. 58: 6038–6045.
- Jung JJ, Chen CY, Mrejen S, Pinazo RG, Xu L, et al. (2014). The incidence of neovascular subtypes in newly diagnosed neovascular age-related macular degeneration. *Am J Ophthalmol*. 158: 769–779.e2.
- Li M, Huisingh C, Messinger J, Marco RD, Ferrara D, et al. (2018). Histology of geographic atrophy secondary to age-related macular degeneration A Multilayer Approach *Retina*. 38: 1937–1953.
- Bhisitkul RB, Mendes TS, Rofagha S, Enanoria W, Boyer DS, et al. (2015). Macular atrophy progression and 7-year vision outcomes in subjects from the ANCHOR, MARINA and HORIZON studies (SEVEN-UP Study) *Am J Ophthalmol*. 159: 915–924.
- Comparison of Age-related Macular Degeneration Treatments Trials (CATT) Research Group, Maguire MG, Martin DF, Ying GS, Jaffe GJ, Daniel E, et al. (2016). Five-year outcomes with anti-vascular endothelial growth factor treatment of neovascular age-related macular degeneration: the Comparison of Age-Related Macular Degeneration Treatments Trials. *Ophthalmology*. 123: 1751–1761.
- Schutze C, Wedl M, Baumann B, Pircher M, Hitzemberger CK, et al. (2015). Progression of retinal pigment epithelial atrophy in antiangiogenic therapy of neovascular age-related macular degeneration. *Am J Ophthalmol*. 159: 1100–1114. e1.
- Solomon SD, Lindsley K, Vedula SS, Krzystolik MG, Hawkin BS. (2014). Anti-vascular endothelial growth factor for neovascular age related macular degeneration *Cochrane Database Syst Rev*. CD005139.
- Rofagha S, Bhisitkul RB, Boyer DS, Sadda SR, Zhang K, for the SEVEN-UP Study Group. (2013). Seven-year outcomes in ranibizumab-treated patients in ANCHOR, MARINA, and HORIZON: a multicenter cohort study (SEVEN-UP). *Ophthalmology*. 120: 2292–2299.
- Rosenfeld PJ, Shapiro H, Tuomi L, Webster M, Elledge J, et al. (2011). MARINA and ANCHOR Study Groups

- Characteristics of patients losing vision after 2 years of monthly dosing in the phase III ranibizumab clinical trials. *Ophthalmology*. 118: 523–530.
19. Altaweel MM, Daniel E, Martin DF, Mittra RA, Grunwald JE, et al. (2015). Outcomes of eyes with lesions composed of >50% blood in the comparison of age-related macular degeneration treatments trials (CATT). *Ophthalmology*. 122: 391-398.
 20. Grewal DS, Gill MK, Sarezky D, Lyon AT, Mirza RG. (2014). Visual and anatomical outcomes following intravitreal aflibercept in eyes with recalcitrant neovascular age-related macular degeneration: 12-month results. *Eye (Lond)*. 28: 895–899.
 21. Yonekawa Y, Andreoli C, Miller JB, Loewenstein JI, SobrinL, et al. (2013). Conversion to aflibercept for chronic refractory or recurrent neovascular age-related macular degeneration. *Am J Ophthalmol*. 156: 29–35.
 22. Yang S, Zhao J, Sun X. (2016). Resistance to anti-VEGF therapy in neovascular age-related macular degeneration: a comprehensive review. *Drug Des Devel Ther*. 10: 1857–1867.
 23. Rofagha S, Bhisitkul RB, Boyer DS, Sadda SR, Zhang K; for the SEVEN-UP Study Group. (2013). Seven-year outcomes in ranibizumab-treated patients in ANCHOR, MARINA, and HORIZON: a multicenter cohort study (SEVEN-UP). *Ophthalmology*. 120: 2292–2299.
 24. Fung AT, Kumar N, Vance SK, Slakter FAT, Klancnik JM, et al. (2012). Pilot study to evaluate the role of high-dose ranibizumab 2.0 mg in the management of neovascular age-related macular degeneration in patients with persistent/recurrent macular fluid <30 days following treatment with intravitreal anti-VEGF therapy (the LAST Study) *Eye (Lond)*. 26: 1181–1187.
 25. Stewart MW, Rosenfeld PJ, Penha FM, Wang F, Yehoshua Z, et al. (2012). Pharmacokinetic rationale for dosing every 2 weeks versus 4 weeks with intravitreal ranibizumab, bevacizumab, and aflibercept (vascular endothelial growth factor trap-eye) *Retina*. 32: 434–457.
 26. Chan CK, Jain A, Sadda S, Varshney N. (2014). Optical Coherence Tomographic and Visual Results at Six Months after Transitioning to Aflibercept for Patients on Prior Ranibizumab or Bevacizumab Treatment for Exudative Age-Related Macular Degeneration (An American Ophthalmological Society Thesis) *Trans Am Ophthalmol Soc*. 112: 160–198.
 27. Singer MA, Awh CC, Sadda S, Freeman VR, Antoszyk AN, Wong P, et al. HORIZON: an open-label extension trial of ranibizumab for choroidal neovascularization secondary to age-related macular degeneration. *Ophthalmology*. 2012;119(6):1175–1183.
 28. Engelbert M, Zweifel SA, Freund KB. (2010). Long-term follow-up for type 1 (subretinal pigment epithelium) neovascularization using a modified "treat and extend" dosing regimen of intravitreal anti-vascular endothelial growth factor therapy. *Retina*. 30: 1368–1375.
 29. Gharbiya M, Iannetti L, Parisi F, De Vico U, Mungo ML, et al. (2014). Visual and anatomical outcomes of intravitreal aflibercept for treatment-resistant neovascular age-related macular degeneration. *Biomed Res Int*. 2014: 273754.
 30. Chang AA, Li H, Broadhead GK, Hong T, Schlub TE, et al. (2014). Intravitreal aflibercept for treatment-resistant neovascular age-related macular degeneration. *Ophthalmology*. 121: 188–192.
 31. Bakall B, Folk JC, Boldt HC, Sohn EH, Stone EM, et al. (2013). Aflibercept therapy for exudative age-related macular degeneration resistant to bevacizumab and ranibizumab. *Am J Ophthalmol*. 156: 15–22.e11.
 32. Tranos P, Vacalis A, Asteriadis S, Koukoulas S, Vachtsevanos A, et al. (2013). Resistance to anti-vascular endothelial growth factor treatment in age-related macular degeneration. *Drug Des Devel Ther*. 7: 485–490.
 33. Heier JS, Brown DM, Chong V, Korobelnik JF, Kaiser PK, et al. (2012). Intravitreal aflibercept (VEGF trap-eye) in wet age-related macular degeneration. *Ophthalmology*. 119: 2537–2548.
 34. Arcinue CA, Ma F, Barteselli G, Sharpsten L, Gomez ML, (2015). One-year outcomes of aflibercept in recurrent or persistent neovascular age-related macular degeneration. *Am J Ophthalmol*. 159: 426–436.e422.
 35. Kuroda Y, Yamashiro K, Miyake M, Yashikawa M, Nakanishi H, et al. (2015). Factors associated with recurrence of age-related macular degeneration after anti-vascular endothelial growth factor treatment: a

- retrospective cohort study. *Ophthalmology*. 122: 2303–2310.
36. Amoaku WM, Chakravarthy U, Gale R, Gavin M, Ghanchi F, et al. (2015). Defining response to anti-VEGF therapies in neovascular AMD. *Eye (Lond)*. 29: 721–731.
 37. Binder S. (2012). Loss of reactivity in intravitreal anti-VEGF therapy: tachyphylaxis or tolerance? *Br J Ophthalmol*. 96: 1–2.
 38. Gasperini JL, Fawzi AA, Khondkaryan A, Lam L, Chong LP, et al. (2012). Bevacizumab and ranibizumab tachyphylaxis in the treatment of choroidal neovascularisation. *Br J Ophthalmol*. 96: 14–20.
 39. Eghoj MS, Sorensen TL. (2012). Tachyphylaxis during treatment of exudative age-related macular degeneration with ranibizumab. *Br J Ophthalmol*. 96: 21–23.
 40. Keane PA, Heussen FM, Ouyang Y, Mokwa N, Walsh AC, et al. (2012). Assessment of differential pharmacodynamic effects using optical coherence tomography in neovascular age-related macular degeneration. *Investigative Ophthalmology and Visual Science*. 53: 1152–1161.
 41. Curcio CA, Zanzottera EC, Ach T, Balaratnasingam C, Freund KB. (2017). Activated Retinal Pigment Epithelium, an Optical Coherence Tomography Biomarker for Progression in Age-Related Macular Degeneration. *Invest Ophthalmol Vis Sci*. 58: B10211–B10226.
 42. Patel KH, Chow CC, Rathod R, Mieler WF, Lim JJ, et al. (2013). Rapid response of retinal pigment epithelial detachments to intravitreal aflibercept in neovascular age-related macular degeneration refractory to bevacizumab and ranibizumab. *Eye (Lond)*. 27: 663–667.
 43. Daniel E, Shaffer J, Ying GS, Grunwald JE, Martin DF, et al. (2016). Outcomes in eyes with retinal angiomatous proliferation in the Comparison of Age-Related Macular Degeneration Treatments Trials (CATT). *Ophthalmology*. 123: 609–616.
 44. Freund KB, Ho IV, Barbazetto IA, Koizumi H, Laud K, et al. (2008). Type 3 neovascularization: the expanded spectrum of retinal angiomatous proliferation. *Retina*. 28: 201–211.
 45. Dansingani KK, Naysan J, Freund KB. (2015). En face OCT angiography demonstrates flow in early type 3 neovascularization (retinal angiomatous proliferation) *Eye (Lond)*. 29: 703–706.
 46. Gharbiya M, Parisi F, Cruciani F, Bozzoni-Pantaleoni F, Pranno F, et al. (2014). Intravitreal anti-vascular endothelial growth factor for retinal angiomatous proliferation in treatment-naïve eyes: long-term functional and anatomical results using a modified PrONTO-style regimen. *Retina*. 34: 298–305.
 47. CATT Research Group, Martin DF, Maguire MG, Ying GS, Grunwald JE, Fine SL, et al. (2011). Ranibizumab and bevacizumab for neovascular age-related macular degeneration. *New England Journal of Medicine*. 364: 1897–1908.
 48. Yuan MZ, Chen LL, Yang JY, Luo MY, Chen YX. (2020). Comparison of OCT and OCTA manifestations among untreated PCV, neovascular AMD, and CSC in Chinese population. *Int J Ophthalmol*. 13: 93–103.
 49. Moon da RC, Lee DK, Kim SH, You YS, Kwon OW. (2015). Aflibercept treatment for neovascular age-related macular degeneration and polypoidal choroidal vasculopathy refractory to anti-vascular endothelial growth factor. *Korean J Ophthalmol*. 29: 226–232.
 50. Wong CW, Wong TY, Cheung CM. (2015). Polypoidal choroidal vasculopathy in Asians. *J Clin Med*. 4: 782–821.
 51. Cheung CM, Li X, Mathur R, Wong EYM, Wong D, et al. (2014). A prospective study of treatment patterns and 1-year outcome of Asian age-related macular degeneration and polypoidal choroidal vasculopathy. *PLoS One*. 9: e101057.
 52. Tsuchihashi T, Mori K, Yeyama K, Yoneya S. (2013). Five-year results of photodynamic therapy with verteporfin for Japanese patients with neovascular age-related macular degeneration. *Clin Ophthalmol*. 7: 615–620.
 53. Suzuki M, Sato T, Spaide RF. (2014). Pseudodrusen subtypes as delineated by multimodal imaging of the fundus. *Am J Ophthalmol*. 157: 1005–1012.
 54. Kim JH, Chang YS, Kim JW, Lee TG, Kim CG. (2015). Prevalence of subtypes of reticular pseudodrusen in newly diagnosed exudative age-related macular degeneration and polypoidal choroidal vasculopathy in Korean patients. *Retina*. 35: 2604–2612.
 55. Schaal KB, Freund KB, Litts KM, Zhang Y, Messinger JD, et al. (2015). Outer retinal tubulation in advanced age-related macular degeneration: optical coherence

- tomographic findings correspond to histology. *Retina*. 35: 1339–1350.
56. Lu X, Sun X. (2015). Profile of conbercept in the treatment of neovascular age-related macular degeneration. *Drug Des Devel Ther*. 9: 2311–2320.
57. Abramsson A, Lindblom P, Betsholtz C. (2003). Endothelial and nonendothelial sources of PDGF-B regulate pericyte recruitment and influence vascular pattern formation in tumors. *J Clin Invest*. 112: 1142–1151.