

## The Endoscopic Treatment in Chronic Pancreatitis: A Systematic Review

Tantau Alina\* and Tantau Marcel

Department of Gastroenterology, Iuliu Hatieganu University of Medicine and Pharmacy, Romania

### ARTICLE INFO

Received Date: January 05, 2022

Accepted Date: January 31, 2022

Published Date: February 01, 2022

### KEYWORDS

Chronic pancreatitis

Endoscopic therapy

Pancreatic stricture

Pancreatic stones

Biliary strictures

Pancreatic stents

Biliary stents

Metallic stents

ESWL

**Copyright:** © 2022 Tantau Alina et al., SL Gastroenterology. This is an open access article distributed under the Creative Commons Attribution License, which permits unrestricted use, distribution, and reproduction in any medium, provided the original work is properly cited.

**Citation for this article:** Tantau Alina, Tantau Marcel. The Endoscopic Treatment in Chronic Pancreatitis: A Systematic Review. SL Gastroenterology. 2022; 4(1):123

### Corresponding author:

Tantau Alina,  
Gastroenterology Department,  
University of Medicine and Pharmacy,  
Romania,  
Email: alitantau@gmail.com

### ABSTRACT

**Background:** In patients with chronic pancreatitis, the pain is the main symptom, sometimes really debilitating, with a negative impact on patient's life quality. There is no etiological therapy for chronic pancreatitis. The goal of the endoscopic treatment of painful chronic pancreatitis is to drain the pancreatic duct, reduce the frequency and severity of pain and resolve local complications of the disease as biliary strictures and pseudo cysts. Few data are available on the long term efficacy of endoscopic treatment.

**Objective:** This review will discuss the endoscopic treatment options in patients with chronic pancreatitis and its local complications.

**Materials and Methods:** A systematic literature review on the endoscopic treatment of chronic pancreatitis was conducted using the electronic databases of ISI Web of Science, Pub Med and Cochrane Library for relevant articles. The electronic search for the review was performed by using the search terms “Chronic pancreatitis” AND “endoscopic therapy” through different criteria. The search was restricted to retrospective studies, prospective studies, Randomized Controlled Trials (RCTs) and case series studies performed between January 1989 and August 2019. PRISMA checklist and flow diagram were adopted for evaluation and reporting. The reference lists of the selected papers were also scanned to find other relevant studies.

**Results:** 832 studies meeting the search criteria and 8 relevant articles found in the edited books about chronic pancreatitis were identified. Duplicates and irrelevant studies were excluded by screening titles and abstracts and assessing full texts. 90 studies were evaluated for full text review. Endoscopic therapy was categorized into four groups as (1) pancreatic strictures; (2) pancreatic stones; (3) pseudo cysts; and (4) biliary strictures.

Most of studies in the literature showed that endoscopic therapy provides good short-term or moderate term results in case of Main Pancreatic Duct (MPD) obstruction caused by strictures and chronic pancreatitis related biliary strictures. In majority of the studies, pseudo cysts represent an excellent indication for endoscopic treatment with long-term results. Nine studies designed to assess the utility of Extracorporeal Shock Wave Lithotripsy (ESWL) in chronic pancreatitis were reviewed. ESWL is widely used for pancreatic stones in patients with painful chronic pancreatitis. Ten studies were reviewed in order to evaluate the Efficacy of Endosonography (EUS) in pseudo cysts drainage. Endosonography-guided techniques allow treatment of almost any pancreatic pseudo cyst. Nine studies conducted to evaluate the efficacy of Fully-Covered Metallic Stents (FCSEMSs) for biliary strictures were reviewed. FCSEMS has

been frequently used and has potent and promising benefits in biliary strictures therapy.

**Conclusion:** In case of MPD obstruction caused by calcifications, ESWL has become a first-line treatment. In case of MPD obstruction caused by stricture(s), endoscopic therapy provides good short term or moderate term results. Pseudo cysts represent an excellent indication for endoscopic treatment with long-term results. Endoscopic drainage of biliary obstruction provides excellent short term but only moderate long term results.

## INTRODUCTION

During the last years, the endoscopic approach in patients with chronic pancreatitis has become only therapeutic, due to the important development of non-invasive imaging techniques [1]. The endoscopic management is recommended in patients in whom the primary medical treatment fails [1]. The chronic pain may be due the pancreatic duct obstruction by strictures or stones with secondary increasing of pressure and ischemia [2], there for the endoscopic duct decompression seems to be a rational approach [3,4] and it can be successfully repeated in case of pain relapses [5,6]. Drainage of the main duct can be proposed as a first-line treatment in patients unfit for surgery or refusing surgery and can also be useful as a “bridge to surgery” therapy [4,7]. Some studies showed an improvement of quality of life after endoscopic treatment [3]. The surgery remains the option treatment in the absence of success of endoscopic treatment [8,9]. The endoscopic treatment of pain in chronic pancreatitis combines several procedures, to restore drainage of the main pancreatic duct: pancreatic sphincterotomy, extraction of pancreatic stones, pancreatic and biliary stenting, and the drainage of pseudo cysts with conventional endoscopy or with Endoscopic Ultrasound (EUS). Extracorporeal Shock Wave Lithotripsy (ESWL) for pancreatic stones may be combined with endoscopic procedures. Recently, Fully-Covered Expandable Metallic Stents (FCSEMSs) are proposed for pancreatic and biliary strictures providing long-term favorable outcomes [2,4,8,10]. The long-term outcomes of endoscopic treatment in patients with chronic pancreatitis are under investigation. Some studies reported the long-term results of surgical treatment are better than endoscopic treatment in patients with dilated pancreatic duct,

stones or strictures [7,9]. In this literature review we intend to explore what are the short- and long term clinical outcomes of endoscopic treatment in patients with chronic pancreatitis and its local complications.

## MATERIALS AND METHODS

### Literature search strategy

A comprehensive literature review was done using the available biomedical databases of PubMed, ISI Web of Science and Cochrane Library. Only studies published between January 1989 to August 2019 in English language were included. Additional relevant articles were recruited from references lists of each of the included studies.

The search terms for all databases consisted of the words [“Chronic pancreatitis” [All Fields] AND “endoscopic therapy” (All Fields)] OR “treatment” [(All Fields), ] “chronic pancreatitis” [(All Fields) AND “pancreatic stents” (All Fields) OR “biliary stents” (All Fields)], [“ESWL” (All Fields) AND “chronic pancreatitis” (All Fields) AND “pancreatic stones” (All Fields) [ “pseudo cysts” [(All Fields)] AND “pancreatitis” (All Fields) AND “plastic stents” (All Fields) OR “metallic stents” [ (All Fields) ].

### Inclusion and exclusion criteria

The relevance of the studies was determined by using the PRISMA 2009 Statement. The assessment of the studies was based on title, abstract, and the full manuscript of the studies. Additional relevant articles were recruited from references lists of each of the included studies.

### The inclusion criteria of the studies assessed are as follows:

(1) prospective studies, retrospective studies, RCTs and case series studies (2) publication in English; (3) availability of the full text; and (4) publication date between January 1989 and August 2019.

### Exclusion criteria of this review were determined as follows:

(1) The article type as reviews, meta-analyses, editorial letters, commentaries, clinical study protocols and case reports; (2) Studies with insufficient information and descriptions; and (3) Duplicate studies in all databases were found by End Note and excluded manually.

### Analysis

Multiple revisions were done by each of the authors to ensure the validity of the extracted information and, to minimize the errors made by individual perception.

## RESULTS

In order to prepare the manuscript, we followed the PRISMA 2009 Statement guidelines.

The literature searches through databases of PubMed, ISI Web of Science and Cochrane Library identified 832 studies meeting the search criteria and 8 relevant articles found in the edited books about chronic pancreatitis. End Note was used to check for duplicate studies. 359 studies were found to be duplicates and were removed. The eligibility of the 493 studies was evaluated by screening the titles and abstracts to see if they met the inclusion criteria. We included different type of studies as retrospective and prospective studies, RCTs, case series studies and excluded all other publication types such as reviews, editorial letters, commentaries, clinical study protocols and case reports. 301 studies were not meeting the inclusion criteria and were excluded. The full-text of the 191 remaining studies was reviewed. 101 of these studies were identified to be irrelevant and excluded. 90 studies were evaluated for full text review.

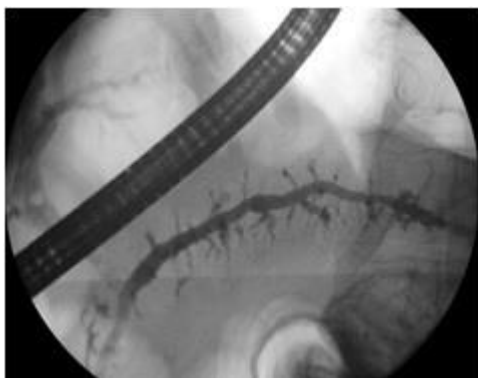


Figure 1: Severe chronic pancreatitis.

## PANCREATIC STRICTURES

The chronic inflammation, fibrosis and the pancreatic stones may lead to the occurrence of pancreatic strictures [5,10] in patients with chronic pancreatitis (figure 1). The Main Duct Pancreatic (MPD) strictures may be single / multiple, dominant / non dominant [11]. Treatment of a dominant MPD stricture is defined as technically successful if at least one stent is inserted across the stricture. The absence of pain (relapse) at 1-year post stent retrieval seems a reasonable and workable definition or clinical success [11]. The Endoscopic Ultrasound with Fine Needle Aspiration (EUS-FNA) or pancreatic brushing are needed to rule out a pancreatic cancer in that patients with

increased risk [12-14]. The endoscopic management of benign pancreatic strictures includes dilatation and stenting [10,11]. Pancreatic sphincterotomy (the major or minor papilla) has been performed prior to MPD stenting in all large studies [5,6,15-21]. In case of difficult catheterization of MPD and in case of cholangitis, jaundice, dilated CBD with cholestasis, pancreatic sphincterotomy is associated with biliary sphincterotomy [22].

The stenting is preferred in symptomatic patients with a single stricture in the MPD in the head of the pancreas better than patients with multiple strictures along the MPD, so-called "chain of lakes" appearance [11]. Using only single plastic stents for a dominant MPD stricture, the majority of the studies showed that the immediately pain relieve is obtained in 65-95% of patients [5-6,16-17,19-21,23] and in 32%-68% of patients during the follow-up (14-58 months) [6,16-17,19-20,23] (table 1). The dilatation is performed prior the stenting with wire guided balloons, bougie or Soehendra stent retriever. Polyethylene 10Fr pancreatic stent are most commonly used and exchanged every three months or "on-demand" if symptoms of occlusion develop [11,18,23]. A retrospective study included patients that received 10 Fr stents, reported the rate of hospitalization for abdominal pain lower than patients who received stents  $\leq$  8.5 Fr [24]. One study showed that from 100 patients with severe chronic pancreatitis and pancreatic duct strictures, successfully treated for pancreatic pain using polyethylene pancreatic stents, the majority (70%) maintain the response after definitive stent removal. However, a significantly higher re-stenting rate was observed in patients with chronic pancreatitis and pancreas divisum [18].

In patients with MPD strictures persisting after 12 months of single plastic stenting, multiple simultaneous stents should be used [25,26]. One study showed that in 84% of patients with multiple pancreatic stents, with a median of three simultaneous stents, inserted for a mean period of 7 months, the pain was relieved after 38 months of follow-up [26]. In a recent study on 48 patients with chronic pancreatitis and a single pancreatic stent through a refractory stricture in a pancreatic head and a long follow up period (median 9,5 years), the patients became asymptomatic in 74,4% after the stent removal. Five patients (10,4%) had persistent strictures after stent removal and 7% had stricture recurrence in a mean time of 26,4 months [26].

Three prospective studies showed that in more than 80% of patients with chronic pancreatitis related strictures and temporary placement (2-3 months) of fully covered SEMs, the pain no relapsed during a mean period of 5 months following the stent removal [27-29]. Recently, few prospective series reported an improvement of pain by using temporary placement of fully covered SEMs [30-33].

Complications associated with plastic stents are mild pancreatitis or worsening of pancreatic pain (average 6.2%, range 4%–39%), sepsis, cholangitis, and post-sphincterotomy bleeding (average, 2.6%, 2.3%, and 1.5%, respectively). Migration of the stent was reported in 2.7%-3.6% of cases

[31,33]. Complications associated with SEMs are stent migration (15%–46%), de novo strictures (16%–27%), severe pain (7%–20%) and FCSEMS removal (15%) [31,33]. Endosonography-guided access and drainage of the MPD can be use in patients with symptomatic MPD obstruction and failed conventional trans papillary drainage. The technique is difficult and rarely use. Two studies with long-term follow-up, reported a complete or major pain relief in 70%–90% of patients [34,35]. The complications occur in approximately 10% of cases and consist in severe pancreatitis, perforation, bleeding, hematoma, migration and occlusion of stents necessitating endoscopic re-intervention (20%–55% of patients) [34-37].

Table 1: Selected series of plastic stenting of MPD strictures in chronic pancreatitis.

Study	No. of patients	Follow-up months	Early pain relief %	Long-term pain relief %	Surgery %
Cremer et al., [5]	75	37	94	NA	15
Ponchon et al., [6]	23	14	74	52	15
Smits et al., [16]	49	34	82	82	6
Vitale et al., [17]	89	43	83	68	12
Binmoeller et al., [24]	93	58	74	65	26
Eleftheriadis et al., [18]	100	69	70	62	4
Ishara et al., [19]	20	21	95	90	NA
Weber et al., [20]	17	24	89	83	NA
Binmoeller et al., [23]	93	108	74	64	NR
Costamagna et al., [25]	19	38	NA	84	NR
Triangli et al., [26]	48	113	74	67	NR

NA not available

NR not reported

## PANCREATIC STONES

The clearance of stones, obstructing the MPD can be perform by ERCP with sphincterotomy and stones extraction, ESWL with the stones fragmentation alone, or combination of these two methods.

The long-term success of endotherapy alone varying between 72 to 86% of cases, the pain is improved in 68 % of patients [38-40]. The success of stones fragmentation by ESWL in a large prospective study was 93% in 1006 patients [41]. ESWL facilitates endoscopic extraction of MDP stones. The presence of a single stone and the localization in the head of pancreas were associated with success of MPD clearance after ESWL [42,43]. A study compared ESWL alone with ESWL followed by ERCP in 55 patients [44] and the only significant difference was the longer hospitalization and a higher cost in

patient with both methods. In patient with pancreatic strictures and stones, ESWL following by endoscopic drainage had good clearance rate and good long-term result [45-51]. In majority of the studies the pancreatic ESWL was associated with 70 to 76% complete MPD clearance and 17 to 20% of patients had partial MPD clearance. In half of the patients the pain was absent or mild-moderate during the 24 months of following treatment and the quality of life was improved in majority after ESWL [41-51] (table 2).

The European guidelines recommend ESWL for the clearance of radio opaque obstructive MPD stones larger than 5mm located in the head/body of the pancreas, and ERCP for MPD stones that are radiolucent or smaller than 5mm [11]. Intraductal laser or electro hydraulic lithotripsy, after failure of ESWL have been demonstrated to have different success rate (47-83%) in small case series [52,53].

**Table 2: Results of pain treatment in chronic pancreatitis after endoscopic extraction and ESWL of pancreatic stones.**

Study	No. of patients	Follow-up months	Early pain relief %	Long-term relief %	Surgery %
Tandan et al., [41]	1006	6	93	84	NR
Adamek et al., [43]	80	40	NR	76	10
Sauebruch et al., [45]	24	24	83	68	8
Delhaye et al., [46]	123	14	85	40	8
Johanns et al., [47]	35	NR	84	NR	NR
Dumonceau et al., [48]	55	24	NR	55 (ESWL alone) 62 (ESWL and endoscopy)	NR
Brand et al., [48]	48	7	NR	45	NR
Inui et al., [50]	504	44	97	78	4
Tadenuma et al., [51]	70	36	97	70	0

NR- not reported

## PANCREATIC PSEUDO CYSTS (PPCS)

Twenty to forty percent of patients with chronic pancreatitis can develop pseudo cysts during the evolution of disease [54] by intraductal hypertension or by the rupture of a pancreatic duct. The indications for PPC treatment are the presence of symptoms, the infection or if it is enlarging and cause obstruction [55]. Endoscopic therapy of PPC is performed by insert a drain from the digestive lumen into PPC ("trans mural drainage"), through papilla ("trans papillary drainage") when exist a direct communication between the PPC and the MPD (in 40-66 % of cases) [56-61], or combination of these methods.

Technical success is definite by the ability to insert at least one stent from PPC to digestive lumen or resolution of PPC [11]. Short-term clinical success is associated with complete relief of the symptoms with the decrease of PPC diameter at least 30-50% at 1 month [38,56-61]. The technical success of trans mural drainage is reported to be present in 85-100 %, the recurrence rate of 10-15% and complication rate of 10-34 % [56-63]. Using EUS with fine needle aspiration the pseudo cyst could be biochemical and cytological evaluated in order to make a differential diagnosis [64]. In the absence of luminal bulging, trans mural drainage should be performed under EUS guidance [65,66].

Cystoduodenostomy should be preferred over cystogastrostomy if both routes are deemed feasible with a higher long-term success rate (83, 1% vs. 64%), with the same morbidity of 10% [62,63]. It should be use at least two double-pigtail plastic stent, at least 2 months and retrieve only after the cyst resolution [56,57]. The early stent removal was

associated with more PPC recurrences [63]. A retrospective study showed that using a single or straight stent for a period  $\leq 6$  weeks increase the risk of failure of endotherapy [62], therefore two double-pigtail plastic stents seem to be the preferable option.

Due to the increased risk of bleeding, the trans mural drainage in presence of portal hypertension should be performed under EUS guidance [67]. The arterial embolization of an arterial pseudo aneurysm should be performed prior to PPC drainage [68].

Plastic stents and metallic stents (FCSEMSs) have been compared for the trans mural drainage of PPCs in some studies which unfortunately comprised only a small percent of patients with chronic pancreatitis. Some authors reported that success and morbidity rate have been similar between plastic stents and FCSEMSs [69-71]. In other studies, majority with acute pancreatitis and Wall off Necrosis (WON) the biliary FCSEMSs and Lumen Apposing Metal Stents (LAMSs) had a higher success rate compared with plastic stents [72-74]. The mean number of procedures required for WON resolution was significantly lower in the LAMS group compared with the FCSEMS and plastic stents groups. Although there was no significant difference between FCSEMSs and LAMSs for WON resolution, the LAMS was more likely to have early adverse events [73].

In some studies, LAMSs were compared with multiple plastic stents for the treatment of peri pancreatic fluid collections (only few patients had a chronic pancreatitis). LAMSs demonstrated a higher clinical success rate with lower morbidity rate [70,71,73,75].



## BILIARY DUCT STRICTURES

About 3-23 % of patients with chronic pancreatitis may develop during the time biliary duct strictures [76] (figure 2) due to the fibrosis, compression by a pseudo cyst or cancer [77]. The stricture related to chronic pancreatitis are the most difficult to treat, in particular if the calcifications are present in the pancreatic head, with a recurrence in 1/3 of cases after temporary insertion of multiple plastic stent simultaneously (figure 3) or of covered SEMSs and in 2/3 of cases after temporary insertion of a single plastic stent [78-87]. The guidelines recommend the endotherapy in case of symptoms, secondary biliary cirrhosis, biliary stones (figure 4), progression of biliary stricture or asymptomatic elevation of serum alkaline phosphatase ( $> 2$  or  $3$  times upper limit of normal values) and/or of serum bilirubin for longer than 1 months [11]. Before the endoscopic stenting of biliary stricture, it should rule out a malignant etiology [77]. Clinical success is present in more than 90 % of patients with temporary simultaneous plastic stents, 80 % in placement of uncovered SEMSs (USEMSs) and 60 % in a single plastic stent [76-81]. Using only a single plastic stents several studies showed an average rate of strictures resolution of 10-38% [82-86]. The complications were more frequent with uncovered SEMSs (40 %) compared with single plastic stent (36 %) and multiple plastic stents (20 %) [87-90].

The USEMSs in patients with chronic pancreatitis have limitations due to the potential of epithelial hyperplasia, occlusion, and the inability to remove the stent, the risk of chronic inflammation and a potential for cholangio carcinoma [87,89]. The single plastic stent and uncovered SEMSs were abandoned due to poor long term results [11]. The Partial Covered Self-Expanding Stents (PCSEMSs) and the fully-covered self-expandable metal stents (FCSEMSs) are promising for the treatment of biliary stricture related to chronic pancreatitis, with long term success rate of 50-80%, low recurrence rate of 14 % and a rate of their removal of 75 % from patients [91-99] (table 3).

Some authors [97] reported good long-term results regarding the improving of pain and resolution of biliary strictures in patients with postoperative stricture with multiple plastic stents placement comparative with covered self-expanding stents. FCSEMSs are effective for refractory benign biliary strictures PCSEMSs and FCSEMSs are easier to remove, offering the

option of temporary placement in patients with CP and associated common duct stricture who failed prior plastic stent therapy [92-96]. PCSEMS left in place over time decrease in patency, requiring additional endoscopic interventions [92,93]. Long-term results were similar between simultaneous plastic stents and FCSEMSs in terms of clinical success, strictures resolution, stricture recurrence and stents migration [93].

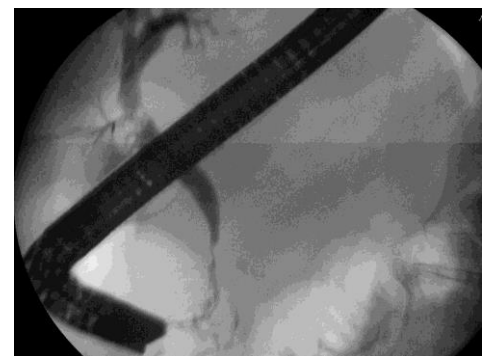

Figure 2: Related chronic pancreatitis CBD stricture.

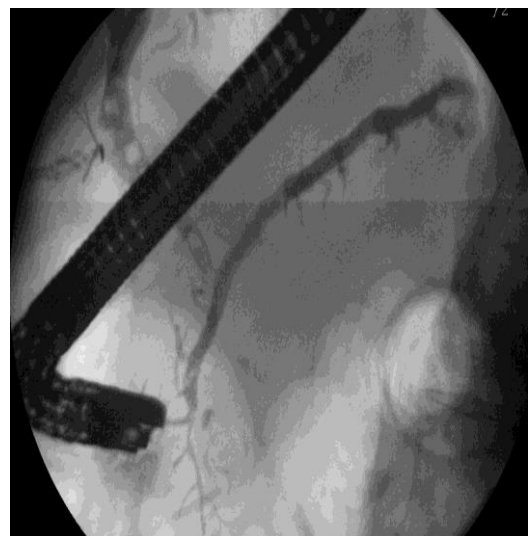

Figure 3: Severe chronic pancreatic with CBD stricture and biliary stones.

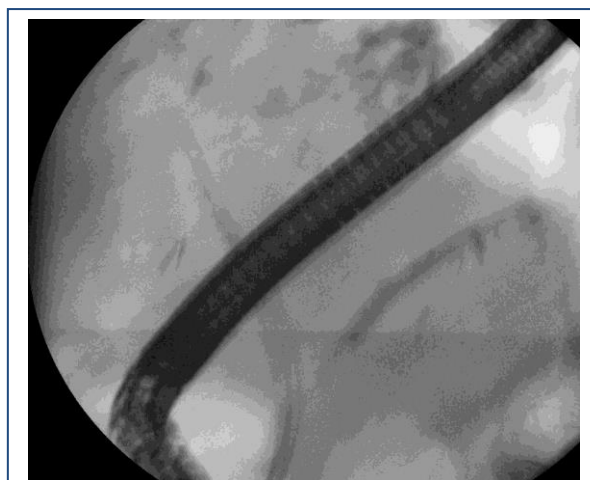

Figure 4: Multiple biliary plastic stenting for chronic pancreatitis related stricture.

Table 3: Selected study of partial or fully-covered self-expandable metal stenting for Common Bile Duct (CBD) strictures in chronic pancreatitis.

Study	No of patients	Follow-up months	Stricture free success %
Haapamäki et al., [93]	60	40	92
Cahen et al., [94]	6	5	75
Behm et al., [95]	20	11	90
Devière et al., [96]	187 (127 with CP)	20,3	90,5 in CP group
Irani et al., [96]	145 (73 with CP)	6	48 in CP group
Tarantino et al., [96]	62 pts. (4 with CP)	15,0	75 in CP group

NA not available

CP chronic pancreatitis

## DISCUSSION

The management of patients with chronic pancreatitis is a therapeutically challenge and must be approached through interdisciplinary collaboration team: gastroenterologist, radiologist and surgeon. In painful chronic pancreatitis, resistant to the medical therapy or in presence of local complications initially approach it should be the minimal endoscopic treatment. In case of MPD obstruction caused by calcifications, ESWL has become a first-line treatment. In a proportion of patients ERCP could be associated to ESWL. In case of MPD obstruction caused by stricture(s), endoscopic therapy provides good short term or moderate term results. Insertion of single

plastic stent is effective but it requires multiple ERCPs for stent exchanges. FCSEMSs have good results regarding pain relieve. Pseudo cysts represent an excellent indication for endoscopic treatment with long-term results similar to those of surgery. Endosonography-guided techniques allow treatment of almost any pancreatic pseudo cyst. Endoscopic drainage of biliary obstruction provides excellent short term but only moderate long term results. Patients without calcifications of the pancreatic head benefit from biliary stenting. Multiple, simultaneous plastic stents and FCSEMSs are superior to single stent placement and may provide good long-term benefit. There are several limitations of this review: inclusion of retrospective studies, small number of patients included in an important number of studies, only few RCTs included in the assessment. Endoscopic treatment can provide good long term outcomes in chronic pancreatitis but further RCTs regarding the utility of FCSEMSs for pancreatic and biliary strictures are needed.

## REFERENCES

1. Frulloni L, Falconi M, Gabbriellini A, Gaia E, Graziani R, et al. (2010). Italian consensus guidelines for chronic pancreatitis. *Dig Liver Dis.* 6: 381-406.
2. Forsmark CE. (2013). Management of Chronic Pancreatitis. *Gastroenterology.* 144: 1282-1291.
3. Pezzilli R, Morselli Labate AM, Ceciliato R, Frulloni L, Cavestro GM, et al. (2005). Quality of life in patients with chronic pancreatitis. *Dig Liver Dis.* 37: 181-189.
4. Delhaye M, Arvanitakis M, Bali M, Matos C, Deviere J. (2005). Endoscopic therapy for chronic pancreatitis. *Scand J Surg.* 94: 143-153.
5. Cremer M, Deviere J, Delhaye M, Baize M, Vandermeeren A. (1991). Stenting in severe chronic pancreatitis: results of medium-term follow-up in seventy-six patients. *Endoscopy.* 23: 171-176.
6. Ponchon T, Bory RM, Hedelius F, Roubein LD, Paliard P, et al. (1995). Endoscopic stenting for pain relief in chronic pancreatitis: results of a standardized protocol. *Gastrointest Endosc.* 42: 452-456.
7. Dite P, Ruzicka M, Zboril V, Novotný I. (2003). A prospective, randomized trial comparing endoscopic and surgical therapy for chronic pancreatitis. *Endoscopy.* 35: 553-558.

8. Elta GH. (2007). Is there a role for the endoscopic treatment of pain from chronic pancreatitis? *N Engl J Med.* 356: 727-729.
9. Devière J, Bell RH Jr, Beger HG, Traverso LW. (2008). Treatment of chronic pancreatitis with endotherapy or surgery: critical review of randomized control trials. *J Gastrointest Surg.* 12: 640-644.
10. Oza VM, Kahaleh M. (2013). Endoscopic management of chronic pancreatitis. *World J Gastrointest Endosc.* 5: 19-28. *doubt*
11. Dumonceau JM, Delhay M, Tringali A, Arvanitakis M, Sanchez-Yague A, et al. (2019). Endoscopic treatment of chronic pancreatitis: European Society of Gastrointestinal Endoscopy (ESGE) Guideline. *Endoscopy.* 51: 179-193. *Changed the title*
12. Eloubeidi MA, Varadarajulu S, Desai S, Wilcox CM. (2008). Value of repeat endoscopic ultrasound-guided fine needle aspiration for suspected pancreatic cancer. *J Gastroenterol Hepatol.* 23: 567-570.
13. Eloubeidi MA, Tamhane A. (2008). Prospective assessment of diagnostic utility and complications of endoscopic ultrasound-guided fine needle aspiration. Results from a newly developed academic endoscopic ultrasound program. *Dig Dis.* 26: 356-363.
14. Varadarajulu S, Tamhane A, Eloubeidi MA. (2005). Yield of EUS-guided FNA of pancreatic masses in the presence or the absence of chronic pancreatitis. *Gastrointest Endosc.* 62:728-736; quiz 751, 753.
15. Farnbacher MJ, Mühldorfer S, Wehler M, Fischer B, Hahn EG, et al. (2006). Interventional endoscopic therapy in chronic pancreatitis including temporary stenting: a definitive treatment? *Scand J Gastroenterol.* 41: 111-117.
16. Smits ME, Badiga SM, Rauws EA, Tytgat GN, Huibregtse K. (1995). Long-term results of pancreatic stents in chronic pancreatitis. *Gastrointest Endosc.* 42: 461-467.
17. Vitale GC, Cothron K, Vitale EA, Rangnekar N, Zavaleta CM, et al. (2004). Role of pancreatic duct stenting in the treatment of chronic pancreatitis. *Surg Endosc.* 18: 1431-1434.
18. Eleftherladis N, Dinu F, Delhay M, Le Moine O, Baize M, et al. (2005). Long-term outcome after pancreatic stenting in severe chronic pancreatitis. *Endoscopy.* 37: 223-230.
19. Ishihara T, Yamaguchi T, Seza K, Tadenuma H, Saisho H. (2006). Efficacy of s-type stents for the treatment of the main pancreatic duct stricture in patients with chronic pancreatitis. *Scand J Gastroenterol.* 41: 744-750.
20. Weber A, Schneider J, Neu B, Meining A, Born P, et al. (2007). Endoscopic stent therapy for patients with chronic pancreatitis: results from a prospective follow-up study. *Pancreas.* 34: 287-294.
21. Boursier J, Quentin V, Le Tallec V, Maurin A, Person B, et al. (2008). Endoscopic treatment of painful chronic pancreatitis: Evaluation of a new flexible multiperforated plastic stent. *Gastroenterol Clin Biol.* 32: 801-805.
22. Kim MH, Myung SJ, Kim YS, Kim HJ, Seo DW, et al. (1998). Routine biliary sphincterotomy may not be indispensable for endoscopic pancreatic sphincterotomy. *Endoscopy.* 30: 697-701.
23. Binmoeller KF, Jue P, Seifert H, Nam WC, Izbicki J, et al. (1995). Endoscopic pancreatic stent drainage in chronic pancreatitis and a dominant stricture: long-term results. *Endoscopy.* 27: 638-644.
24. Sauer BG, Gurka MJ, Ellen K, Shami VM, Kahaleh M. (2009). Effect of pancreatic duct stent diameter on hospitalization in chronic pancreatitis: does size matter? *Pancreas.* 38: 728-731.
25. Costamagna G, Bulažić M, Tringali A, Pandolfi M, Gabbriellini A, et al. (2006). Multiple stenting of refractory pancreatic duct strictures in severe chronic pancreatitis: long-term results. *Endoscopy.* 38: 254-259.
26. Tringali A, Bove V, Vadalà di Prampero SF, Boškoski I, Familiari P, et al. (2019). Long-term follow-up after multiple plastic stenting for refractory pancreatic duct strictures in chronic pancreatitis. *Endoscopy.*
27. Park DH, Kim MH, Moon SH, Lee SS, Seo DW, et al. (2008). Feasibility and safety of placement of a newly designed, fully covered self-expandable metal stent for refractory benign pancreatic ductal strictures: a pilot study (with video). *Gastrointest Endosc.* 68: 1182-1189.
28. Sauer B, Talreja J, Ellen K, Ku J, Shami VM, et al. (2008). Temporary placement of a fully covered self-expandable metal stent in the pancreatic duct for management of symptomatic refractory chronic pancreatitis: preliminary data (with videos). *GastrointestEndosc.* 68: 1173-1178.



29. Moon SH, Kim MH, Park DH, Song TJ, Eum J, et al. (2010). Modified fully covered self-expandable metal stents with anti migration features for benign pancreatic duct strictures in advanced chronic pancreatitis, with a focus on the safety profile and reducing migration. *Gastrointest Endosc.* 72: 86-91.
30. Matsubara S, Sasahira N, Isayama H, Takahara N, Mizuno S, et al. (2016). Prospective pilot study of fully covered self-expandable metal stents for refractory benign pancreatic duct strictures: long-term outcomes. *Endosc Int Open.* 4: 1215-1222.
31. Oh D, Lee JH, Song TJ, Park DH, Lee SK, et al. (2018). Long-term outcomes of 6-mm diameter fully covered self-expandable metal stents in benign refractory pancreatic ductal stricture. *Dig Endosc.* 30: 508-515.
32. Tringali A, Vadalà di Prampero SF, Landi R, Bove V, Familiari P, et al. (2018). Fully covered self-expandable metal stents to dilate persistent pancreatic strictures in chronic pancreatitis: long-term follow-up from a prospective study. *Gastrointest Endosc.* 88: 939-946.
33. Farnbacher MJ, Radespiel-Tröger M, König MD, Wehler M, Hahn EG, et al. (2006). Pancreatic endoprotheses in chronic pancreatitis: criteria to predict stent occlusion. *Gastrointest Endosc.* 63: 60-66.
34. Tessier G, Bories E, Arvanitakis M, Hittelet A, Pesenti C, et al. (2007). EUS-guided pancreatogastrostomy and pancreatobulbostomy for the treatment of pain in patients with pancreatic ductal dilatation inaccessible for transpapillary endoscopic therapy. *Gastrointest Endosc.* 65: 233-241.
35. Tyberg A, Sharaiha RZ, Kedia P, Kumta N, Gaidhane M, et al. (2017). EUS-guided pancreatic drainage for pancreatic strictures after failed ERCP: a multicenter international collaborative study. *Gastrointest Endosc.* 85: 164-169.
36. Chen YI, Levy MJ, Moreels TG, Hajjjeva G, Will U, et al. (2017). An international multicenter study comparing EUS-guided pancreatic duct drainage with enteroscopy-assisted endoscopic retrograde pancreatography after Whipple surgery. *Gastrointest Endosc.* 85: 170-177.
37. Shah RJ, Shah JN, Waxman I, Kowalski TE, Sanchez-Yague A, et al. (2015). Safety and efficacy of endoscopic ultrasound-guided drainage of pancreatic fluid collections with lumen-apposing covered self-expanding metal stents. *Clin Gastroenterol Hepatol* 13: 747-752.
38. Rösch T, Daniel S, Scholz M, Huibregtse K, Smits M, Schneider, et al. (2002). Endoscopic treatment of chronic pancreatitis: a multicenter study of 1000 patients with long-term follow-up. *Endoscopy.* 34: 765-771.
39. Sherman S, Ruffolo TA, Hawes RH, Lehman GA. (1991). Complications of endoscopic sphincterotomy. A prospective series with emphasis on the increased risk associated with sphincter of Oddi dysfunction and nondilated bile ducts. *Gastroenterology.* 101:1068-1075.
40. Sherman S, Lehman GA, Hawes RH, Ponich T, Miller LS, et al. (1991). Pancreatic ductal stones: frequency of successful endoscopic removal and improvement in symptoms. *GastrointestEndosc.* 37: 511-517.
41. Tandan M, Reddy DN, Santosh D, Vinod K, Ramchandani M ,et al. (2010). Extracorporeal shock wave lithotripsy and endotherapy for pancreatic calculi – a large single center experience. *Indian J Gastroenterol.* 29: 143-148.
42. Dumonceau JM, Devière J, Le Moine O, Delhaye M, Vandermeeren A, et al. (1996). Endoscopic pancreatic drainage in chronic pancreatitis associated with ductal stones: long term results. *Gastrointest Endosc.* 43: 547-555.
43. Adamek HE, Jakobs R, Buttmann A, Adamek MU, Schneider AR, et al. (1999). Long term follow up of patients with chronic pancreatitis and pancreatic stones treated with extracorporeal shock wave lithotripsy. *Gut.* 45: 402-405.
44. Dumonceau JM, Costamagna G, Tringali A, Vahedi K, Delhaye M, et al. (2007). Treatment for painful calcified chronic pancreatitis: extracorporeal shock wave lithotripsy versus endoscopic treatment: a randomised controlled trial. *Gut.* 56: 545-552.
45. Sauerbruch T, Holl J, Sackmann M, Paumgartner G. (1989). Extracorporeal shock wave lithotripsy of pancreatic stones. *Gut.* 30: 1406-1411.
46. Delhaye M, Vandermeeren A, Baize M, Cremer M. (1992). Extracorporeal shock-wave lithotripsy of pancreatic calculi. *Gastroenterology.* 102: 610-620.
47. Johanns W, Jakobeit C, Greiner L, Janssen J. (1996). Ultrasound-guided extracorporeal shock wave lithotripsy

- of pancreatic ductal stones: six years' experience. *Can J Gastroenterol*.10: 471-475.
48. Dumonceau JM, Devière J, Le Moine O, Delhayé M, Vandermeeren A, et al. (1996). Endoscopic pancreatic drainage in chronic pancreatitis associated with ductal stones: long-term results. *Gastrointest Endosc*. 43: 547-555.
  49. Brand B, Kahl M, Sidhu S, Nam VC, Sriram PV, et al. (2000). Prospective evaluation of morphology, function, and quality of life after extracorporeal shockwave lithotripsy and endoscopic treatment of chronic calcific pancreatitis. *Am J Gastroenterol*. 95: 3428-3438.
  50. Inui K1, Tazuma S, Yamaguchi T, Ohara H, Tsuji T, et al. (2005). Treatment of pancreatic stones with extracorporeal shock wave lithotripsy: results of a multicenter survey. *Pancreas*. 30: 26-30.
  51. Tadenuma H, Ishihara T, Yamaguchi T, Tsuchiya S, Kobayashi A, et al. (2005). Long-term results of extracorporeal shockwave lithotripsy and endoscopic therapy for pancreatic stones. *Clin Gastroenterol Hepatol*. 3: 1128-1135.
  52. Hirai T, Goto H, Hirooka Y, Itoh A, Hashimoto S, et al. (2004). Pilot study of pancreatoscopic lithotripsy using a 5-fr instrument: selected patients may benefit. *Endoscopy*. 36: 212-216.
  53. Howell DA, Dy RM, Hanson BL, Nezhad SF, Broaddus SB. (1999). Endoscopic treatment of pancreatic duct stones using a 10F pancreatoscope and electrohydraulic lithotripsy. *Gastrointest Endosc*. 50: 829-833.
  54. Andrén-Sandberg A, Dervenis C. (2004). Pancreatic pseudocysts in the 21st century. Part I: classification, pathophysiology, anatomic considerations and treatment. *JOP*. 5: 8-24.
  55. Baron TH, Harewood GC, Morgan DE, Yates MR. (2002). Outcome differences after endoscopic drainage of pancreatic necrosis, acute pancreatic pseudocysts, and chronic pancreatic pseudocysts. *Gastrointest Endosc*. 56: 7-17.
  56. Barthet M, Lamblin G, Gasmi M, Vitton V, Desjeux A, et al. (2008). Clinical usefulness of a treatment algorithm for pancreatic pseudocysts. *Gastrointest Endosc*. 67: 245-252.
  57. Hookey LC, Debroux S, Delhayé M, Arvanitakis M, Le Moine O, et al. (2006). Endoscopic drainage of pancreatic- fluid collections in 116 patients: a comparison of etiologies, drainage techniques, and outcomes. *Gastrointest Endosc*. 63: 635- 643.
  58. Smits ME, Rauws EA, Tytgat GN, Huibregtse K. (1995). The efficacy of endoscopic treatment of pancreatic pseudocysts. *Gastrointest Endosc*. 42: 202-207.
  59. Beekingham IJ, Krige JE, Bornman PC, Terblanche J. (1997). Endoscopic management of pancreatic pseudocysts. *Br J Surg*. 84: 1638-1645.
  60. Funnell IC, Bornman PC, Krige JE, Beningfield SJ, Terblanche J. (1994). Endoscopic drainage of traumatic pancreatic pseudocyst. *Br J Surg*. 81: 879-881.
  61. Cremer M, Deviere J, Engelholm L. (1989). Endoscopic management of cysts and pseudocysts in chronic pancreatitis: long-term follow-up after 7 years of experience. *Gastrointest Endosc*. 35: 1-9.
  62. Arvanitakis M, Delhayé M, Bali MA, Matos C, De Maertelaer V, et al. (2007). Pancreatic-fluid collections: a randomized controlled trial regarding stent removal after endoscopic transmural drainage. *Gastrointest Endosc*. 65: 609-619.
  63. Cahen D, Rauws E, Fockens P, Weverling G, Huibregtse K, et al. (2005). Endoscopic drainage of pancreatic pseudocysts: long-term outcome and procedural factors associated with safe and successful treatment. *Endoscopy*. 37: 977-983.
  64. Breslin N, Wallace MB. (2002). Diagnosis and fine needle aspiration of pancreatic pseudocysts: the role of endoscopic ultrasound. *Gastrointest Endosc Clin N Am*. 12: 781-790.
  65. Lopes CV, Pesenti C, Bories E, Caillol F, Giovannini M. (2007). Endoscopic-ultrasound guided endoscopic transmural drainage of pancreatic pseudocysts and abscesses. *Scand J Gastroenterol*. 42: 524-529.
  66. Kahaleh M, Shami VM, Conaway MR, Tokar J, Rockoff T, et al. (2006). Endoscopic ultrasound drainage of pancreatic pseudocyst: a prospective comparison with conventional endoscopic drainage. *Endoscopy*. 38: 355-359.

67. Sriram PV, Kaffes AJ, Rao GV, Reddy DN. (2005). Endoscopic ultrasound-guided drainage of pancreatic pseudocysts complicated by portal hypertension or by intervening vessels. *Endoscopy*. 37: 231-235.
68. Kun-Chun Chiang, Tsung-Hsing Chen, Jun-Te Hsu. (2014). Management of chronic pancreatitis complicated with a bleeding pseudoaneurysm, *World J Gastroenterol*. 20: 16132-16137.
69. Lee BU, Song TJ, Lee SS, Park DH, Seo DW, et al. (2014). Newly designed, fully covered metal stents for endoscopic ultrasound (EUS)-guided transmural drainage of peripancreatic fluid collections: a prospective randomized study. *Endoscopy*. 46: 1078-1084.
70. Bapaye A, Dubale NA, Sheth KA, Bapaye J, Ramesh J, et al. (2017). Endoscopic ultrasonography-guided transmural drainage of walled-off pancreatic necrosis: comparison between a specially designed fully covered bi-flanged metal stent and multiple plastic stents. *Dig Endosc*. 29: 104-110.
71. Mukai S, Itoi T, Baron TH, Sofuni A, Itokawa F, et al. (2015). Endoscopic ultrasound-guided placement of plastic vs. biflanged metal stents for therapy of walled-off necrosis: a retrospective single-center series. *Endoscopy*. 47: 47-55.
72. Chandran S, Efthymiou M, Kaffes A, Chen JW, Kwan V, et al. (2015). Management of pancreatic collections with a novel endoscopically placed fully covered self-expandable metal stent: a national experience (with videos). *Gastrointest Endosc*. 81: 127-135.
73. Siddiqui AA, Kowalski TE, Loren DE, Khalid A, Soomro A, et al. (2017). Fully covered self-expanding metal stents versus lumen-apposing fully covered self-expanding metal stent versus plastic stents for endoscopic drainage of pancreatic walled-off necrosis: clinical outcomes and success. *Gastrointest Endosc*. 85: 758-765.
74. Sharaiha RZ, DeFilippis EM, Kedia P, Gaidhane M, Boumitri C, et al. (2015). Metal versus plastic for pancreatic pseudocyst drainage: clinical outcomes and success. *Gastrointest Endosc*. 82: 822-827.
75. Ang TL, Kongkam P, Kwek AB, Orkoonsawat P, Rerknimitr R, et al. (2016). A two-center comparative study of plastic and lumen-apposing large diameter self-expandable metallic stents in endoscopic ultrasound-guided drainage of pancreatic fluid collections. *Endosc Ultrasound*. 5: 320-327.
76. Devière J, Devaere S, Baize M, Cremer M. (1990). Endoscopic biliary drainage in chronic pancreatitis. *Gastrointest Endosc*. 36: 96-100.
77. Devière J, Baize M, Vandermeeren A, Buset M, Delhaye M, et al. (1990). Endoscopic stenting for biliary strictures. *Acta Gastroenterol Belg*. 55: 295-305.
78. Catalano MF, Linder JD, George S, Alcocer E, Geenen JE. (2004). Treatment of symptomatic distal common bile duct stenosis secondary to chronic pancreatitis: comparison of single vs. multiple simultaneous stents. *Gastrointest Endosc*. 60: 945-952.
79. Draganov P, Hoffman B, Marsh W et al. (2002). Long-term outcome in patients with benign biliary strictures treated endoscopically with multiple stents. *Gastrointest Endosc*. 55: 680-686.
80. Pozsár J, Sahin P, László F et al. (2004). Medium-term results of endoscopic treatment of common bile duct strictures in chronic calcifying pancreatitis with increasing numbers of stents. *J Clin Gastroenterol*. 38: 118-123.
81. Costamagna G, Tringali A, Mutignani M, Perri V, Spada C, et al. (2010). Endotherapy of postoperative biliary strictures with multiple stents: results after more than 10 years of follow-up. *Gastrointest Endosc*. 72: 551-557.
82. Cahen DL, van Berkel AM, Oskam D, Rauws EA, Weverling GJ, et al. (2005). Bruno MJ. Long-term results of endoscopic drainage of common bile duct strictures in chronic pancreatitis. *Eur J Gastroenterol Hepatol*. 17: 103-108.
83. Eickhoff A, Jakobs R, Leonhardt A, Eickhoff JC, Riemann JF. (2001). Endoscopic stenting for common bile duct stenoses in chronic pancreatitis: results and impact on long-term outcome. *Eur J Gastroenterol Hepatol*. 13: 1161-1167.
84. Vitale GC, Reed DN, Nguyen CT, Lawhon JC, Larson GM. (2000). Endoscopic treatment of distal bile duct stricture from chronic pancreatitis. *Surg Endosc*. 14: 227-231.
85. Smits ME, Rauws EA, van Gulik TM, Gouma DJ, Tytgat GN, et al. (1996). Long-term results of endoscopic stenting and surgical drainage for biliary stricture due to chronic pancreatitis. *Br J Surg*. 83: 764-768.

86. Barthet M, Bernard JP, Duval JL, Affriat C, Sahel J. (1994). Biliary stenting in benign biliary stenosis complicating chronic calcifying pancreatitis. *Endoscopy*. 26: 569-572.
87. Devière J, Cremer M, Baize M, Love J, Sugai B, et al. (1994). Management of common bile duct stricture caused by chronic pancreatitis with metal mesh self expandable stents. *Gut*. 35: 122-126.
88. Kiehne K, Fölsch UR, Nitsche R. (2000). High complication rate of bile duct stents in patients with chronic alcoholic pancreatitis due to noncompliance. *Endoscopy*. 32: 377-380.
89. van Berkel AM, Cahen DL, van Westerlo DJ, Rauws EA, Huibregtse K, et al. (2004). Self-expanding metal stents in benign biliary strictures due to chronic pancreatitis. *Endoscopy*. 36: 381-384.
90. Eickhoff A, Jakobs R, Leonhardt A, Eickhoff JC, Riemann JF. (2003). Self-expandable metal mesh stents for common bile duct stenosis in chronic pancreatitis: retrospective evaluation of long-term follow-up and clinical outcome pilot study. *Z Gastroenterol*. 41: 649-654.
91. Kahaleh M, Behm B, Clarke BW, Brock A, Shami VM, et al. (2008). Temporary placement of covered self-expandable metal stents in benign biliary strictures: a new paradigm? (with video). *Gastrointest Endosc*. 67: 446-454.
92. Cantu P, Hookey LC, Morales A, Le Moine O, Devière J. (2005). The treatment of patients with symptomatic common bile duct stenosis secondary to chronic pancreatitis using partially covered metal stents: a pilot study. *Endoscopy*. 37: 735-739.
93. Haapamäki C, Kylänpää L, Udd M, Lindström O, Grönroos J, et al. (2015). Randomized multicenter study of multiple plastic stents vs. covered self-expandable metallic stent in the management of biliary stricture in chronic pancreatitis. *Endoscopy*. 47: 605-610.
94. Cahen DL, Rauws EA, Gouma DJ, Fockens P, Bruno MJ. (2008). Removable fully covered self-expandable metal stents in the treatment of common bile duct strictures due to chronic pancreatitis: a case series. *Endoscopy*. 40:697-700.
95. Behm B, Brock A, Clarke BW, Ellen K, Northup PG, et al. (2009). Partially covered self-expandable metallic stents for benign biliary strictures due to chronic pancreatitis. *Endoscopy*. 41: 547-551.
96. Devière J, Nageshwar Reddy D, Püspök A, Ponchon T, Bruno MJ, et al. (2014). Successful management of benign biliary strictures with fully covered self-expanding metal stents. *Gastroenterology*. 147: 385-395.
97. Irani S, Baron TH, Akbaer A, Lin OS, Gluc KM, et al. (2014). Endoscopic Treatment of Benign Biliary Strictures Using Covered Self-Expandable Metal Stents (CSEMS). *Dig Dis Sciences*. 59: 152-160.
98. Coté GA, Slivka A, Tarnasky P, Mullardy DK, Elmunzer BJ, et al. (2016). Effect of Covered Metallic Stents Compared with Plastic Stents on Benign Biliary Stricture Resolution a Randomized Clinical Trial. *JAMA*. 315: 1250-1257.
99. Tarantino I, Mangiavillano B, Di Mitri R, Barresi L, Mocciaro F, et al. (2012). Fully covered self-expandable metallic stents in benign biliary strictures: a multicenter study on efficacy and safety. *Endoscopy*. 44: 923-927.