

## Submucosal Colonic Lipoma - An Uncommon Yet Important Entity

Kevin Kim-Jun Teh<sup>1</sup>, Lai-Mun Wang<sup>2</sup>, Shu-Wen Tay<sup>1</sup>, Ramesh Wijaya<sup>3</sup>, Malcolm Teck-Kiang Tan<sup>1</sup> and Jeannie Peng-Lan Ong<sup>1\*</sup>

<sup>1</sup>Department of Gastroenterology and Hepatology, Changi General Hospital, Singapore

<sup>2</sup>Department of Laboratory Medicine, Changi General Hospital, Singapore

<sup>3</sup>Department of General Surgery, Changi General Hospital, Singapore

### ARTICLE INFO

Received Date: January 01, 2022

Accepted Date: January 28, 2022

Published Date: January 31, 2022

### KEYWORDS

Submucosal lipoma

Intussusceptions

Colonic lipomas

**Copyright:** © 2022 Jeannie Peng-Lan Ong et al., SL Gastroenterology. This is an open access article distributed under the Creative Commons Attribution License, which permits unrestricted use, distribution, and reproduction in any medium, provided the original work is properly cited.

**Citation for this article:** Kevin Kim-Jun Teh, Lai-Mun Wang, Shu-Wen Tay<sup>1</sup>, Ramesh Wijaya, Malcolm Teck-Kiang Tan and Jeannie Peng-Lan Ong. Submucosal Colonic Lipoma - An Uncommon Yet Important Entity. SL Gastroenterology. 2022; 4(1):122

### Corresponding author:

Jeannie Peng-Lan Ong,  
Department of Gastroenterology and  
Hepatology, Changi General Hospital,  
Singapore Health Services, Singapore,

Email: jeannie.ong.p.l@singhealth.com.sg

### ABSTRACT

Colonic lipomas are benign submucosal adipose tumors. Most colonic lipomas are diagnosed incidentally during radiological imaging or colonoscopy. However, large lesions greater than 4cm in size may cause non-specific abdominal symptoms or result in complications such as gastrointestinal bleeding, perforation, intussusceptions or obstruction. The development of symptoms correlates with the size of the lesion. Resection is recommended for these large lesions, while lesions smaller than 2cm in size are managed conservatively. No recommendations have been proposed for borderline sized lesions (2 to 4cm). Colonic lipomas have also been reported to occur in conjunction with epithelial hyperplasia and villous adenomas. The endoscopic appearance of such lipomas can mimic malignancy. We present a case of asymptomatic 3cm submucosal lipoma at the proximal transverse colon with an overlying sessile serrated adenoma which was surgically resected.

A 56 year old man with a known proximal transverse colon submucosal lipoma presented with recurrent episodes of abdominal bloating associated with alterations in his bowel habits. A repeat colonoscopy showed an ulcerated mass at the proximal transverse colon at the same site as the previously known colonic lipoma. Biopsies showed scattered mitotic figures but were inconclusive. A staging CT scan confirmed a lipomatous lesion with surrounding hyperaemia suspicious of a primary malignancy. A laparoscopic segmental transverse colectomy was performed. Histology showed a submucosal lipoma with an overlying sessile serrated adenoma with low grade dysplasia as well as reactive lymph nodes.

### INTRODUCTION

Lipomas are the most common non-epithelial benign tumours of the gastrointestinal tract [1], and are most frequently seen in the colon [2]. They are usually diagnosed incidentally in patients undergoing either radiological imaging or colonoscopy, where they are identified as submucosal, sessile polypoid masses. Majority of them are small and asymptomatic [3]. However, lesions larger than 4cm in size often cause non-specific symptoms including intermittent abdominal discomfort and altered bowel habits. Alarming symptoms such as gastrointestinal bleeding, perforation, intussusceptions or obstruction are less common. The development of symptoms



correlates with the size of the tumour [4,5]. We present a case of an ulcerated colonic lipoma mimicking a malignant tumour in a patient with intermittent abdominal discomfort and altered bowel habits.

### CASE REPORT

A 56 year old male presented to our department with a 2 month history of daily abdominal bloating and discomfort. He also reported change in stool consistency from type 4 to type 5-6 on the Bristol stool chart [6], associated with loss of appetite, loss of weight of 5 kilograms and episodic per-rectal bleeding. Physical examination was unremarkable. He was evaluated 4 years prior after presenting with positive stool occult blood. He was otherwise asymptomatic. He underwent a colonoscopy during which a large submucosal lesion measuring approximately 2.5cm was found at the proximal transverse colon (Figure 1). The overlying mucosa was endoscopically normal and multiple biopsies were taken using a radial jaw biopsy forceps. The submucosal lesion did not demonstrate the classic "pillow-sign". After repeated biopsies of the lesion, there was no extrusion of yellowish fat. Histology from the biopsies of the lesion revealed normal colonic mucosa. Computed Tomography (CT) imaging showed a lobulated lesion of fat density measuring 3.1 x 2.2 x 2.0cm in the proximal transverse colon, likely representing the submucosal lesion detected at colonoscopy (Figure 2). The imaging features were that of a lipoma. He was managed conservatively. Given his clinical symptoms, he was scheduled for a repeat colonoscopy which showed an approximately 3cm pedunculated mass in the proximal transverse colon, at the same location of the previously known colonic lipoma (Figure 3A,3B). The overlying mucosa was erythematous and with multiple focal areas of superficial ulceration. The colonoscope was able to traverse past the lesion smoothly and the rest of the colon was otherwise normal. The colonic mass did not exhibit the typical features of a lipoma as the mucosa was abnormal. The clinical concern was that of a primary malignancy or lipo-sarcomatous transformation and multiple biopsies were taken endoscopically. He underwent repeat CT imaging which showed colonic thickening and enhancement within the proximal transverse colon surrounding the previously known lipomatous lesion associated with peri-colonic

hyperaemia. There was no significant increase in size of the lesion radiologically, with it measuring 2.8 x 3.0cm. There was also a small sub-centimetre lymph node within the peri-colonic fat (Figure 4). Radiologically, it was reported to be concerning for malignancy with no evidence of metastatic disease. Histologically (Figure 5), the colonic mucosa showed predominantly ulceration with granulation tissue. In the vicinity of the ulcer bed, scattered atypical epithelioid to spindled cells including pseudo-lipomatous changes were seen in the lamina propria. Immunohistochemical studies were non-contributory. However, a negative MDM-2 gene amplification test [Fluorescence In-Situ Hybridisation FISH probe: LSI MDM2 (12q15)/ CEP12] result helped exclude a liposarcoma and the pathology impression was that the overall features were concerning for a mesenchymal tumour which may not have been adequately represented on mucosal biopsies. Given the overall clinical impression of a possible mesenchymal tumour, endoscopic ultrasound was not performed. He was referred for a surgical evaluation. He was counselled on the option of laparoscopic segmental colectomy given that he was symptomatic with an ulcerated colonic lesion. He opted for surgical intervention and underwent laparoscopic segmental transverse colectomy uneventfully. Pathological examination of the resected specimen (Figure 6,7) showed a submucosal lipoma 2.5cm in maximal dimension. In addition, apart from superficial mucosal ulceration, the overlying epithelium away from the ulcer exhibited flat hyperplastic type serrated architecture with focal adenomatous change of low grade dysplasia (Figure 8,9). The overall appearance was consistent with a sessile serrated adenoma with low grade dysplasia. Three enlarged lymph nodes sampled showed benign reactive features. The overlying epithelium exhibits flat hyperplastic serrated changes in keeping with a sessile serrated adenoma. Focal low grade dysplasia (inset, 200x magnification) characterized by nuclear enlargement, elongation and pseudo-stratification is identified.



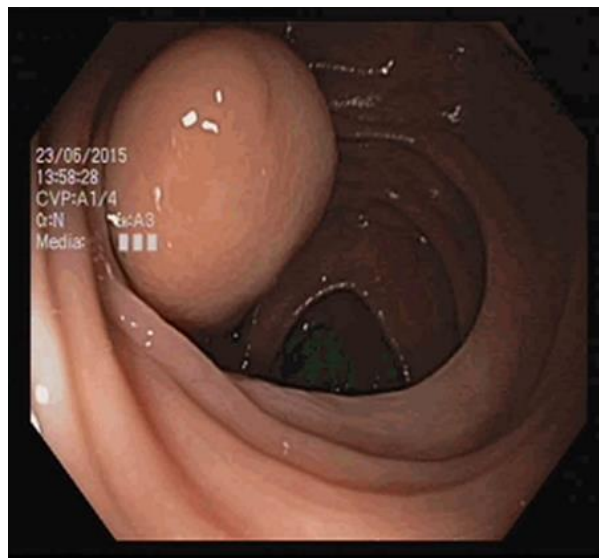


Figure 1: Initial colonoscopy findings.

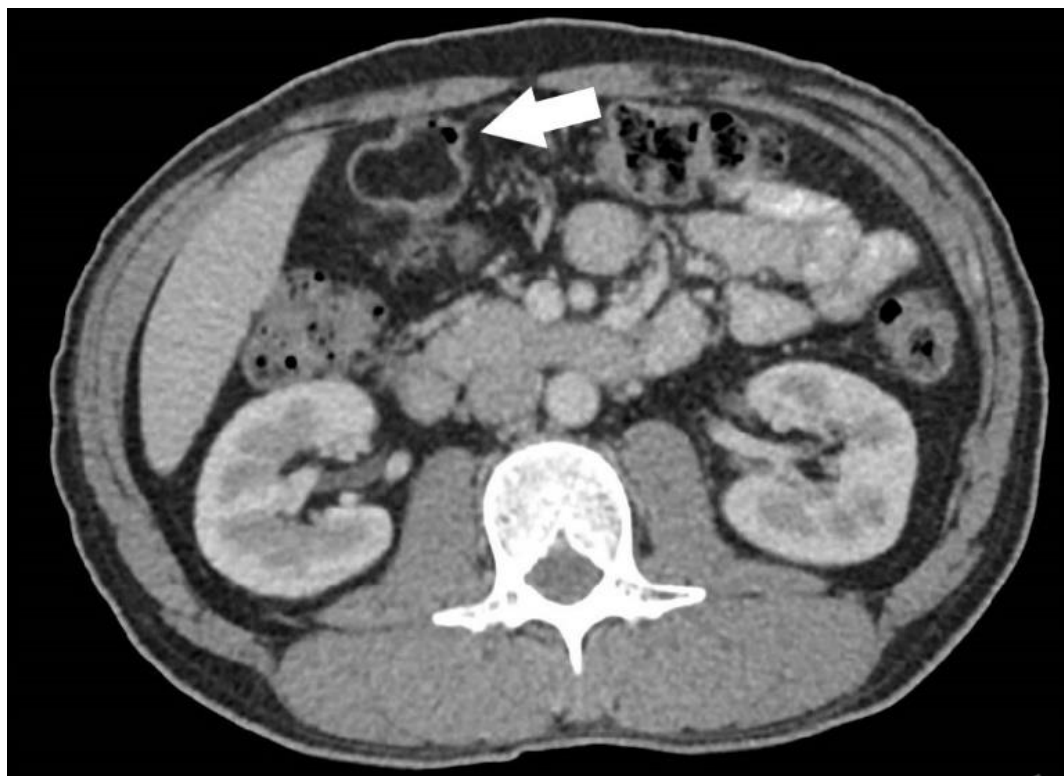
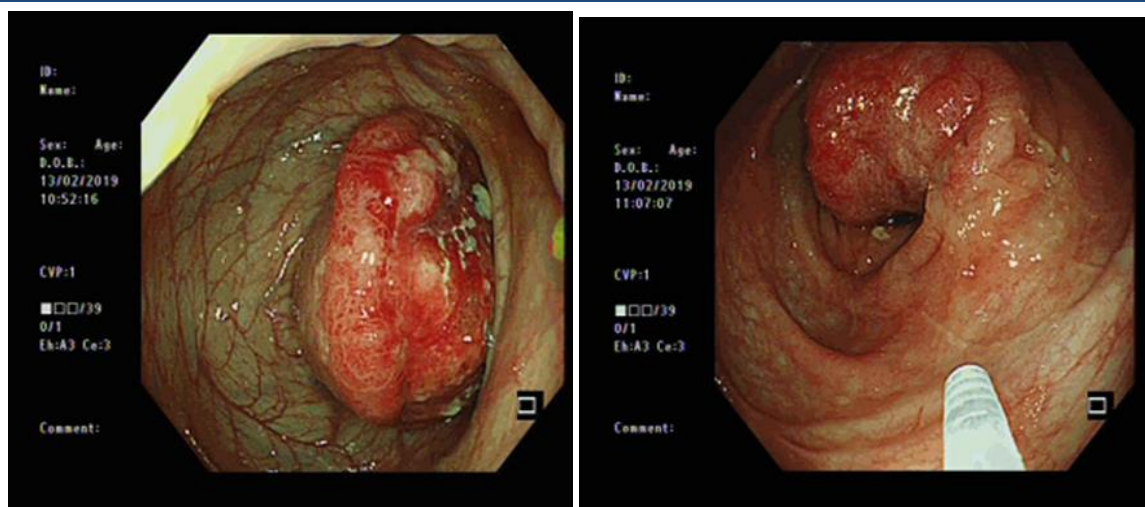


Figure 2: Initial CT imaging findings.





3A

3B

Figure 3A, 3B: Repeat colonoscopy findings.

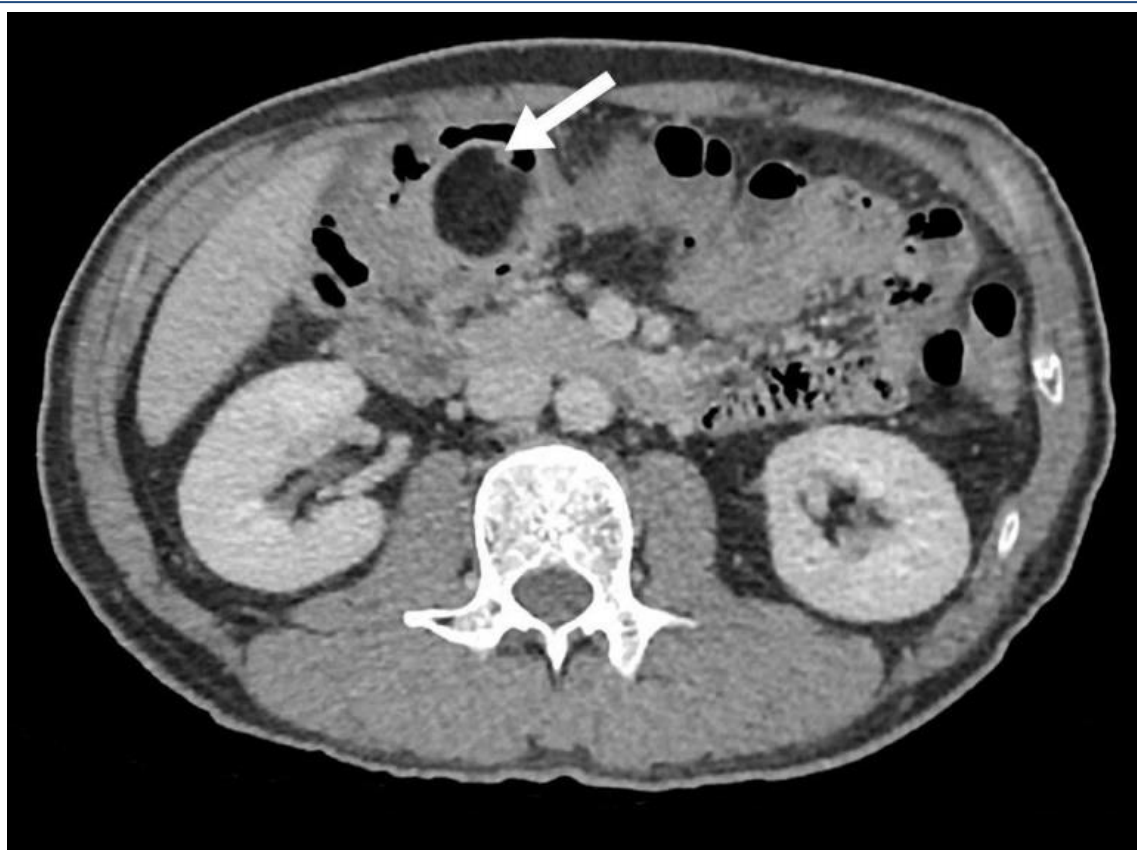


Figure 4: Repeat CT imaging findings.



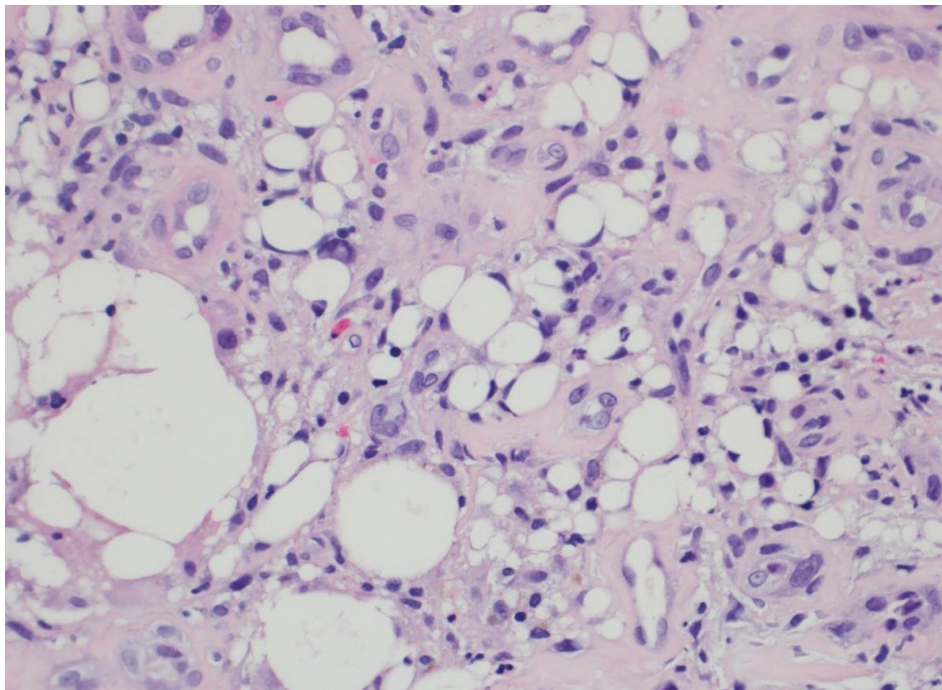


Figure 5: H&E section (200 x magnifications) of the endoscopic biopsy showing atypical cells associated with pseudo-lipomatous changes. Other findings, not illustrated, include ulceration with granulation tissue.

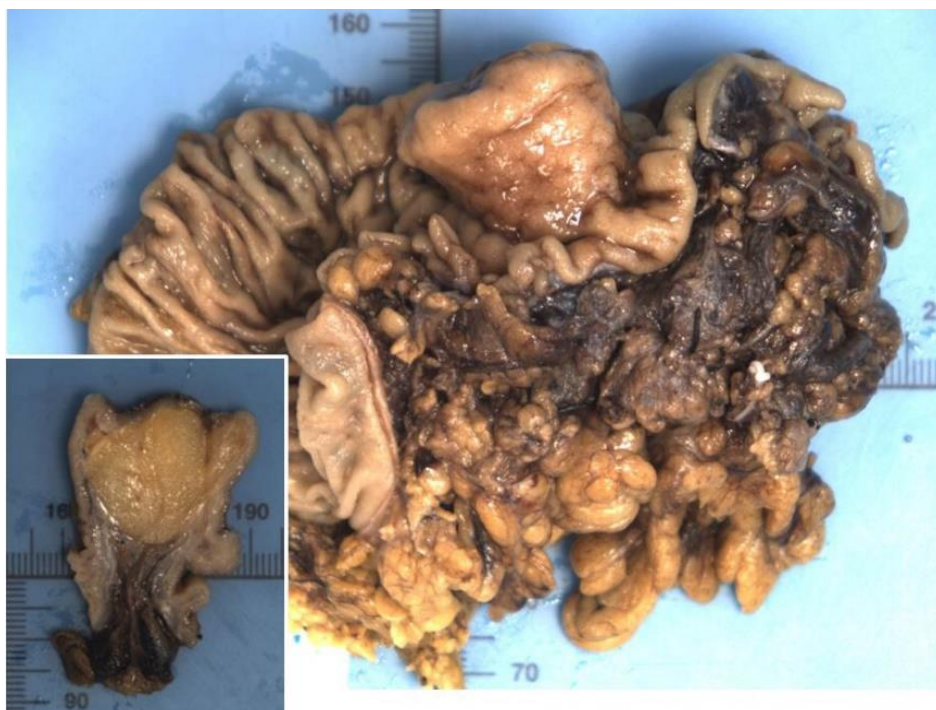

Figure 6: Macroscopic image of the proximal transverse colon segmental resection specimen shows a polypoid 2.5 cm tumour. Cross-section view of the tumour (inset) illustrates a submucosal yellow fatty tumour with smooth boundaries.



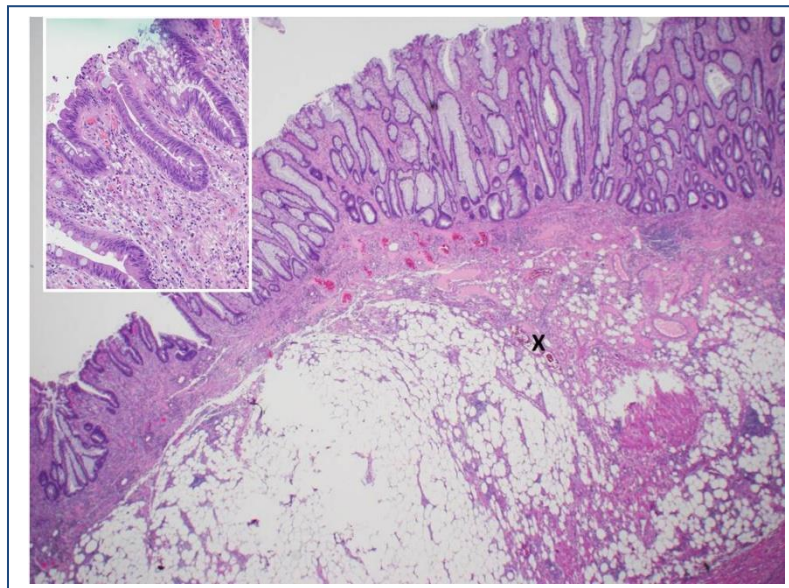


Figure 7: Histology (H&E, 20x magnification) of the resected tumour shows a submucosal lipoma with a small area of haemorrhagic ischaemic change (X), where cells with atypical pseudo-lipomatous changes (similar to pre-operative endoscopic biopsy) were noted. The mucosal ulceration and adjacent lipoma intra-lesional atypical pseudo-lipomatous change were felt to be related local ischaemic injury from either intussusception or polyp torsion effects. On small biopsy material, as in our case, such atypia has posed initial diagnostic challenges requiring further fluorescence in-situ hybridization for MDM2 amplification to exclude liposarcoma.

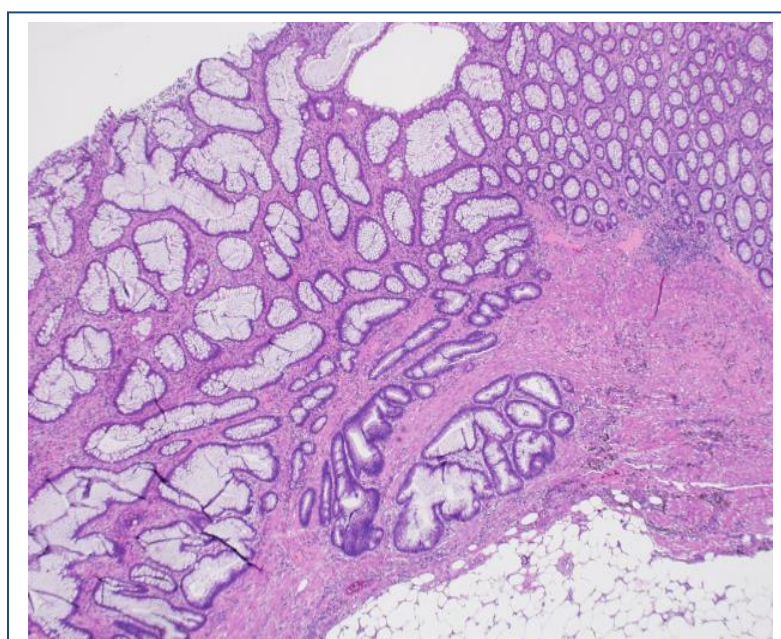
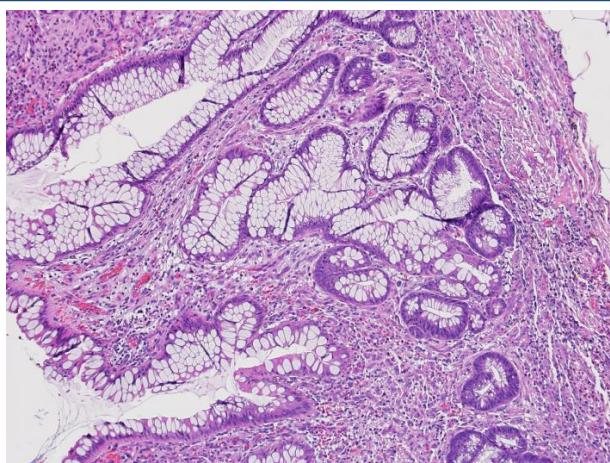




Figure 8: H&E section (40x magnification) demonstrates transition of normal mucosa 'N' and sessile serrated adenoma 'S'.



Figures 9: H&E section (100x magnification) showing features of sessile serrated adenoma characterized by basal crypt dilatation with serration.

## DISCUSSION

Colonic lipomas, whilst uncommon, with an estimated incidence of 0.2% to 4.4% [7], represent the most frequently seen benign non-epithelial derived tumour of the gastrointestinal tract [2]. They are more prevalent in women and have a peak incidence in the fifth to sixth decade of life [8]. They are most commonly seen in the right hemicolon (more than 70%), with the transverse colon being the least common location [9]. Discoveries of colonic lipomas are largely incidental during radiological investigations or colonoscopy. On CT imaging, they are ovoid or pear shaped, with sharp margins. Absorption densities range from -40 to -120 Hounsfield units [10], consistent with its typical fatty composition. However, smaller size colonic lipomas may not be evident on CT imaging. Endoscopically, typical features [11,12] include the “pillow sign” (depression or pillowing of the tumour when pressed by forceps) and the “naked fat sign” (extrusion of fat at the

biopsy site). Colonic lipomas are generally asymptomatic [13], with symptoms correlating with size. When larger than 4cm, they have been described as giant colonic lipomas [14] and are reportedly symptomatic in 75% of patients [4,5]. Giant colonic lipomas often cause intermittent non-specific symptoms including abdominal discomfort and alterations in bowel habits. Severe complications such as perforation, intussusceptions or obstruction rarely occur [15], but may result in the development of mucosal ulceration and bleeding [9]. These ulcerated lesions found on colonoscopy may mimic malignancy at presentation. The histological report of the resected lesion in our case was suggestive of a sessile serrated adenoma with low grade dysplasia overlying the lipoma. Polyps or hyperplastic epithelium overlying colonic lipomas have been reported sporadically [16,17]. Infact, several cases of colonic lipomas with overlying villous adenomas or other presentations mimicking carcinomas have also been reported [18-20]. The underlying mechanism resulting in the development of these overlying mucosal changes remains unknown, but it has been postulated that chronic trauma due to passage of stools or recurrent intussusceptions leads to hyperplasia and subsequent adenomatous transformation [19]. Malignant transformation from a lipoma to a liposarcoma is extremely rare. Liposarcomas are thought to occur de novo [21], and few cases of primary colonic liposarcomas have been reported in the literature. Colonic liposarcomas have been found in conjunction with retroperitoneal liposarcomas [22], with treatment considerations generally referencing those for retroperitoneal tumors [23]. Immunohistochemistry for MDM-2 aids in the differential diagnosis of liposarcoma from other adipocytic neoplasms [24]. With regard to management of colonic lipomas, both endoscopic and surgical approaches can be



considered, although no consensus is available regarding which procedure is preferred. Small lesions less than 2cm in size are largely managed conservatively when diagnosis is not in doubt. Surgery is commonly performed for large lesions greater than 4cm in size [9]. Endoscopic resection is generally recommended as a safe therapeutic method with low risk of complications for colonic lipomas that are pedunculated or less than 2 cm in size [25]. Historically, endoscopic resection of tumours larger than 2cm in size was thought to be associated with higher rates of complications, including perforation and bleeding [2]. However, multiple case reports have demonstrated favourable outcomes, with lipomas up to 11cm in size safely removed using newer endoscopic techniques such as endoloop ligation [26-28]. With continued advancement of endoscopic resection techniques, we can expect the overall complication rates of the procedure to be further reduced. When colonic lipomas are complicated by intussusception, bleeding or bowel obstruction, surgical resection is the treatment of choice [2]. Care of patients with colonic lipomas can be improved. At present, there is neither consensus nor evidence-based guidelines regarding optimal management. Patients with colonic lipomas between 2 to 4cm in size can potentially go on to develop significant complications, and may benefit from elective resection. As mentioned earlier, the epithelium overlying colonic lipomas can also undergo hyperplasia or adenomatous transformation; this has been reported in cases with lipomas as small as 9mm [16], necessitating removal in most instances. Furthermore, malignant transformation of the colonic lipoma itself, while rare, remains a possibility. The overall incidence of these complications remain unclear and more work needs to be done before clinicians can provide accurate and evidence-based counselling to patients diagnosed with colonic lipomas. Our patient was known to have a 3cm transverse colon lipoma which was rightfully managed conservatively when initially diagnosed, given the existing experience and recommendations of various authors. However, he went on to develop symptoms and was postulated to have intermittent subclinical episodes of intussusception leading to the development of mucosal ulceration despite remaining stable in size. Of note, it did not cross the commonly quoted threshold of 4cm. On hindsight, he may have benefited from endoscopic or surgical resection

when the colonic lipoma was first diagnosed. We opine that management of patients found to have asymptomatic "borderline" lesions (between 2 to 4cm in size) should be evaluated on a case-by-case basis with elective resection being considered, although more evidence is required to support our recommendation.

## CONCLUSION

Colonic lipomas represent clinically significant entities that warrant appropriate individualized management. Majority of these tumours are small, asymptomatic and managed conservatively when they are less than 2cm in size. Large lesions greater than 4cm in size that are symptomatic warrant endoscopic or surgical resection. When complicated by intestinal obstruction or intussusceptions, surgical resection is the treatment of choice [2]. Advancements in endoscopic resection techniques, along with favourable complication rates, should feature prominently in the decision-making process of the management of patients with borderline sized lesions.

Gastroenterologists, radiologists, pathologists and colorectal surgeons need to be aware of this entity and its potential complications. International consensus on the management of colonic lipomas would be helpful, especially for borderline sized lesions.

## REFERENCES

1. Tascilar O, Cakmak GK, Gun BD, Uçan BH, Balbaloglu H, et al. (2006). Clinical Evaluation of submucosal colonic lipomas: decision making. *World J Gastroenterol.* 12: 5075-5077.
2. Nallamotheu G, Adler DG. (2011). Large colonic lipomas. *Gastroenterol Hepatol (N Y).* 7: 490-492.
3. Ryan J, Martin JE, Pollock DJ. (1989). Fatty tumours of the large intestine: a clinico-pathological review of 13 cases. *Br J Surg.* 76: 793-796.
4. Rogy MA, Mirza D, Berlakovich G, Winkelbauer F, Rauhs R. (1991). Submucous large-bowel lipomas-presentation and management. An 18-year study. *Eur J Surg.* 157: 51-55.
5. Bahadursingh AM, Robbins PL, Longo WE. (2003). Giant submucosal sigmoid colon lipoma. *Am J Surg.* 186: 81-82.



6. Lewis SJ, Heaton KW. (1997). Stool form scale as a useful guide to intestinal transit time. *Scand J Gastroenterol.* 32: 920-924.
7. Vecchio R, Ferrara M, Mosca F, Ignoto A, Latteri F. (1996). Lipomas of the large bowel. *Eur J Surg.* 162: 915-919.
8. Michowitz M, Lazabnik N, Noy S, Lazebnik R. (1985). Lipoma of the colon. A report of 22 cases. *Am Surg.* 51: 449-454.
9. Gould DJ, Morrison CA, Liscum KR, Silberfein EJ. (2011). A lipoma of the transverse colon causing intermittent obstruction: a rare cause for surgical intervention. *Gastroenterol Hepatol (NY).* 7: 487-490.
10. Heiken JP, Forde KA, Gold RP. (1982). Computed tomography as a definite method for diagnosing gastrointestinal lipoma. *Radiology.* 142: 409-414.
11. El-Khalil T, Mourad FH, Uthman S. (2000). Sigmoid lipoma mimicking carcinoma: case report with review of diagnosis and management. *Gastrointest Endosc.* 51: 405-406.
12. Yoshimura H, Murata K, Takase K, Nakano T, Tameda Y. (1997). A case of lipoma of the terminal ileum treated by endoscopic removal. *Gastrointest Endosc.* 46: 461-463.
13. Bardaji M, Roset F, Camps R, Sant F, Fernández-Layos MJ. (1998). Symptomatic colonic lipoma: differential diagnosis of large bowel tumors. *Int J Colorectal Dis.* 13: 1-2.
14. Gordon RT, Beal JM. (1978). Lipoma of the colon. *Arch Surg.* 113: 897-899.
15. Castro EB, Stearns MW. (1972). Lipoma of the large intestine: a review of 45 cases. *Dis Colon Rectum.* 15: 441-444.
16. Yeom JO, Kim SY, Jang EC, Yu JY, Chang ED, et al. (2013). Colonic lipoma covered by hyperplastic epithelium: case report. *World Journal of Clinical Cases.* 1: 124-127.
17. Lancet F, Alberti LE, Alberti-Flor JJ. (2004). Diminutive colon polyp coexisting with a large lipoma: an endoscopic 'rarity'. *Can J Gastroenterol.* 18: 178.
18. Huh KC, Lee TH, Kim SM, Im EH, Choi YW, et al. (2006). Intussuscepted sigmoid colonic lipoma mimicking carcinoma. *Dig Dis Sci.* 51: 791-795.
19. Capra F, Zorcolo L, Scintu F, Mascia R, Casula G. (2007). Giant sigmoid lipoma covered by a villous adenoma. *Int J Colorectal Dis.* 22: 563-564.
20. Martin P, Sklow B, Adler DG. (2008). Large colonic lipoma mimicking colon cancer and causing colonic intussusception. *Dig Dis Sci.* 53: 2826-2827.
21. Peterson JJ, Kransdorf MJ, Bancroft LW, O'Connor ML. (2003). Malignant fatty tumors: classification, clinical course, imaging appearance and treatment. *Skeletal radiol.* 32: 493-503.
22. Choi YY, Kim YJ, Jin SY. (2010). Primary liposarcoma of the ascending colon: a rare case of mixed type presenting as hemoperitoneum combined with other type of retroperitoneal liposarcoma. *BMC Cancer.* 10: 239.
23. Sawayama H, Yoshida N, Miyamoto Y, Uchihara T, Toihata T, et al. (2017). Primary colonic well-differentiated/dedifferentiated liposarcoma of the ascending colon: a case report. *Surg Case Rep.* 3: 96.
24. Thway K, Flora R, Shah C, Olmos D, Fisher C. (2012). Diagnostic utility of p16, CKD4, and MDM2 as an immunohistochemical panel in distinguishing well-differentiated and dedifferentiated liposarcoma from other adipocytic tumors. *Am J Surg Pathol.* 36: 462-469.
25. Jiang L, Jiang LS, Li FY, Ye H, Li N, et al. (2007). Giant submucosal lipoma located in the descending colon: a case report and review of the literature. *World J Gastroenterol.* 13: 5664-5667.
26. Yu HG, Ding YM, Tan S, Luo HS, Yu JP. (2007). A safe and efficient strategy for endoscopic resection of large, gastrointestinal lipoma. *Surg Endosc.* 21: 265-269.
27. Jansen JB, Temmerman A, Tjhe-Wensing JW. (2010). Endoscopic removal of large colonic lipomas. *Ned Tijdschr Geneesk.* 154: A2215.
28. Kaltenbach T, Milkes D, Friedland S, Soetikno R. (2008). Safe endoscopic treatment of large colonic lipomas using endoscopic looping technique. *Dig Liver Dis.* 40: 958-961.