

Anesthesia in Ocular Surgery

Sudarshan Khokhar, Sourabh Verma, Chirakshi Dhull*

Dr. Rajendra Prasad Centre for Ophthalmic Science, AIIMS, India

ARTICLE INFO

Received Date: January 20, 2022

Accepted Date: February 15, 2022

Published Date: February 18, 2022

KEYWORDS

Anaesthesia
Peribulbar
Nasociliary
Retrobulbar

Copyright: © 2022 Chirakshi Dhull et al., SL Journal of Anesthesia & Critical Care. This is an open access article distributed under the Creative Commons Attribution License, which permits unrestricted use, distribution, and reproduction in any medium, provided the original work is properly cited.

Citation for this article: Sudarshan Khokhar, Sourabh Verma, Chirakshi Dhull. Anaesthesia in Ocular Surgery. SL Journal of Anesthesia & Critical Care. 2022; 3(1):115

Corresponding author:

Chirakshi Dhull,
Dr. Rajendra Prasad Centre for
Ophthalmic Science, AIIMS, New Delhi,
India.
Email: chirakshi@gmail.com

ABSTRACT

Anaesthesia is required during ophthalmic surgeries so that surgical procedure can be performed without causing any discomfort to the patient. Type of anaesthesia depends upon type and duration of surgery, patient cooperation and surgeon's preference. Over the years, a wide range of anesthetic techniques have been developed and have undergone modifications so as to provide better anesthesia with ease and minimum complications. Here we are going to discuss about the history, techniques and new modifications in the field of ocular anaesthesia.

HISTORY

Eye surgeries were being performed without anaesthesia for over 1000 years. In mid-19th century ether and chloroform were used as anaesthetic agent during ocular surgeries. Though effective as anaesthetic agents, they induced vomiting and led to high intracranial and abdominal pressure which was not ideal for delicate eye surgeries [1]. Topical ocular anaesthesia was first introduced by Carl Koller in 1884. He first demonstrated tissue numbing properties of cocaine hydrochloride on a dog and later used 4% solution as a topical anaesthetic while performing surgery on a glaucoma patient [1]. Later Herman Knapp used retrobulbar injection of cocaine while performing enucleation. In the year 1904, Einborn synthesized procaine and established it as a useful agent for retrobulbar anaesthesia. In late 1980s Dr. David and Mandal introduced peribulbar anaesthesia and was later popularized for cataract surgery on a large scale by Charles Kelman. With the advent of faster and safer phacoemulsification techniques there has been a steady shift towards topical anaesthesia in recent years.

RELEVANT ANATOMY

Orbit is grossly comparable to a four sided pyramid with medial walls of both orbits being parallel to each other and lateral wall of orbits being at 90 degrees to each other. Medial wall of orbit is formed by a thin lamina papyracea which can be perforated during blocks and can result in orbital emphysema, cellulitis or even abscess. Globe lies in the anterior part of the orbit being closer to roof and lateral wall of orbit. Posterior part of orbit is occupied by fat muscles and nerves. The four recti originate from the annulus of Zinn near the orbital apex and insert anterior to equator. These along with intermuscular septa form a cone inside which lies the optic nerve, oculomotor nerve, nasociliary nerve, abducent nerve, ciliary ganglion and blood vessels. Trochlear nerve lies outside the cone and supplies superior oblique. Retrobulbar anaesthetic agents often fail to anaesthetize it because of its extra-conal

location. Corneal, perilimbal and superonasal conjunctiva is supplied by nasociliary nerve. Rest of the conjunctiva is supplied by frontal, lacrimal and infraorbital nerves.

ROLE OF ORBITAL: GLOBE SPATIAL RELATIONSHIP

Normally the anatomical equator of globe lies slightly anterior to the lateral orbital rim. The spatial relationship between orbit and globe is expressed as the distance between the tip of the cornea and infraorbital rim. In a forward set globe this distance is more than 8 mm, with lax eyelids and a wide palpebral aperture. Such globes are at high risk of damage to retrobulbar nerves and vessels during blocks. In a deep set globe this distance is less than 8 mm along with tight lids and narrow palpebral aperture and there is relatively higher chance of globe perforation during blocks.

PREOPERATIVE EVALUATION

Detailed history and systemic examination should be carried out for every patient before any needle assisted block. Pre-operative assessment and optimisation of blood pressure and blood sugar should be done. A more detailed evaluation including ECG and heart evaluation may be required in

patients greater than 60 years of age, especially if there is a history of any cerebro or cardiovascular event. Patients on anticoagulant and antiplatelet therapies need not to discontinue it before surgeries with minimal risk of bleeding such as cataract extraction [2]. However, many authorities recommend discontinuing antiplatelet therapy around 1 week before surgery based on studies which have shown higher prevalence of systemic bleeding in patients on combination therapy [3]. For orbital and lid surgeries with higher risk of bleeding there should be a discussion among the surgeon, anaesthetist and patients about the possible pros and cons of discontinuing anticoagulant and antiplatelet therapy. International normalised ratio should be within the normal therapeutic range on the day of surgery in such patients. An increased risk of thromboembolic events has been documented with discontinuation of these therapies before ocular surgeries [4].

CLASSIFICATION

Various techniques of ophthalmic anaesthesia can be classified as given in Figure 1.

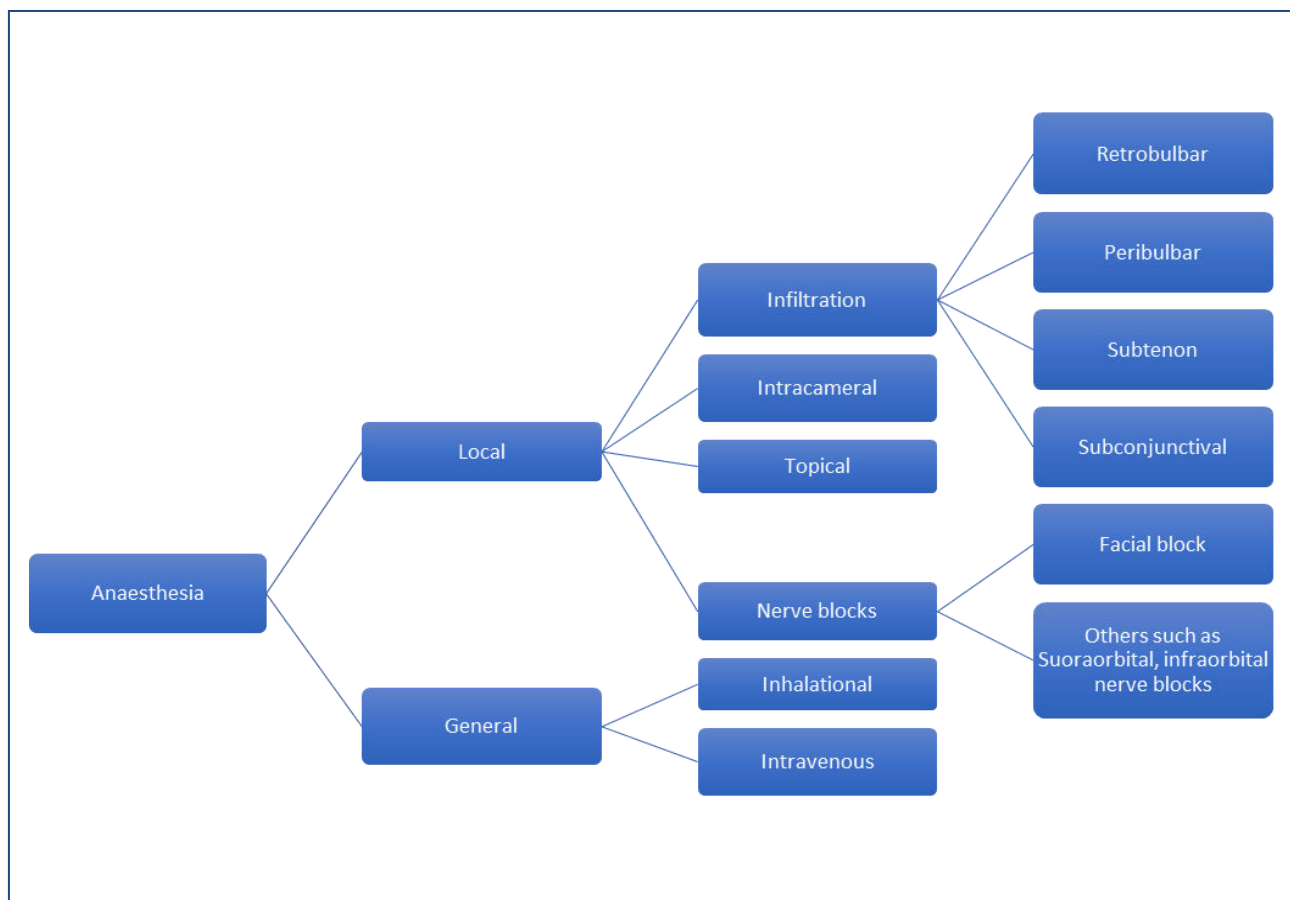


Figure 1: Classification of techniques of ophthalmic anaesthesia

Akinetic Techniques

Techniques which ensure akinesia during surgeries are very useful in uncooperative patients and make surgery easier even for skilled surgeons. Infiltrative anaesthesia is indicated for procedures which require significant manipulation of ocular structures and its adnexa.

Needle Based Techniques

Retrobulbar block: In this technique the anaesthetic solution is injected directly into the intraconal compartment. After preparation of skin with povidone iodine, a 31 mm long, 23 gauge needle is inserted through the skin in the infraorbital quadrant. Classically insertion was done at the junction of medial two third and lateral one third of the lower orbital margin called Atkinson's site. However, this site is no longer recommended due to close proximity of needle to inferior rectus and oblique muscles and neurovascular bundle supplying inferior oblique. Iatrogenic damage to these structures can result in excessive bleeding intra-operatively and diplopia in the post-operative period [5]. In the modern technique of retrobulbar block, needle is inserted just above the junction of inferior and lateral orbital wall, as laterally as possible, with bevel facing the globe. With the eye in primary gaze, needle is first moved tangential to the globe and then once equator is crossed, it is directed upwards and posteriorly into the intraconal space [6]. After insuring that no blood vessel has been entered by aspirating, about 4-5 ml of anaesthetic agent is injected. All the muscles except trochlear nerve are well blocked by this technique. After injection pressure is applied over the globe digitally or with the help of super pinky to ensure spread of anaesthetic agent. Intermittent pressure is preferred to prevent occlusion of vessels. Nasociliary and long ciliary nerves are also blocked which results in complete anaesthesia of globe. For achieving complete akinesia of eyelids additional injection of 2.5 ml lignocaine above and below medial canthus might be required.

AGENT USED

Most commonly used anaesthetic agent is lignocaine and bupivacaine. While Lignocaine has a quick onset and short duration of action, bupivacaine has a slow but sustained effect. A cocktail is prepared by mixing 1500 IU of Hyluronidase in 30 ml 2% lignocaine solution and then mixing 3ml of this with 2 ml of 0.5% bupivacaine. Hyluronidase is a seratiopetidase

which improves the penetration of anaesthetic agents by loosening the connective tissue by its depolymerising action thus improving the speed of onset [7,8]. It has no role in improving the quality or duration of anaesthesia or akinesia [8]. It is mostly used in a concentration of 15 IU/ml.

Ropivacaine and levobupivacaine are newer amide drugs which have shown usefulness as anaesthetic agents [9,10].

Clonidine is a centrally acting hypotensive agent which has shown to reduce the anaesthetic requirement of inhaled sedative and hypnotics. Addition of 1mg/kg of clonidine to the above mixture has shown to increase efficacy and duration of blocks [11,12]. Initially used dose of 2mg/kg is associated with higher incidence of neurologic and cardiac complications such as epilepsy and hypotension. Addition of 25 microgram fentanyl has also shown to potentiate anaesthetic action of above mentioned drugs [13]. Addition of rocuronium and magnesium sulphate to lignocaine-bupicaine solution shortens the time of onset of anaesthesia without any obvious side effect [14].

Addition of adrenaline (1:100000) causes vasoconstriction, slows down the absorption of anaesthetic, prolongs the duration of action and reduces haemorrhage.

Addition of 8.4% sodium bicarbonate to raise the pH increases the duration of action as more drug is present the base form for action.

Peribulbar Block

Here the anaesthetic agent is injected into the extraconal space. There is free communication between intraconal and extraconal space. Though, higher volume might be required than retrobulbar injection it avoids complications associated with it. It is an equally efficient and less painful procedure. Peribulbar anaesthesia also results in better orbicularis akinesia.

With patient looking in primary gaze a 26 gauge, 25 mm long needle is inserted as laterally as possible in the inferotemporal quadrant. The needle is moved along the orbital floor and the depth of insertion is limited by the hub of needle reaching the plane of iris. After negative aspiration of blood around 5ml of anaesthetic solution is injected. There is a significant increase in pressure inside the orbit after it. Pressure is applied over the globe digitally or with help of superpinkie or Honan's balloon to ease the spread of agent and reduce backpressure. Ocular

digital compression is done with 3 fingers pressed over a sterile pad of cotton placed over upper lid. For every 30 seconds of compression a release of 5 seconds is given to allow for blood circulation. Honan's balloon applies a pressure of 30 mm Hg. Pressure is applied for 10 to 20 minutes.

A medial peribulbar injection can be given for augmentation of block if needed. A 26 gauge needle is inserted between medial caruncle and canthus with bevel towards the globe. Needle is first moved along the medial orbital wall and inserted to a depth of 15 to 20 mm. 3 to 5 ml of anaesthetic solution is injected after negative aspiration. Injection in the superomedial quadrant should be avoided as this is the most vascular quadrant of orbit and is associated with higher chance of lid haemorrhage. There is also a higher chance of globe perforation here as globe lies closer to roof [15].

Complications of Needle Blocks

Systemic complications: Systemic complications occur due to inadvertent intra-arterial injection of anaesthetic agent. Retrograde flow through the ophthalmic artery into the internal carotid artery can result in neurological features which depend on the amount that has reached and the area which is affected. During retrobulbar injections the duramater around optic nerve might be perforated which can result in anaesthetic agent reaching subarachnoid space. Signs and symptoms may include numbness, dizziness, shivering, amaurosis, loss of consciousness, tinnitus, vertigo, paraplegia, quadriplegia, seizures etc [16,17]. Brainstem anaesthesia can result in respiratory arrest. Both lignocaine and bupivacaine are cardiotoxic and can cause bradycardia and hypotension.

Orbital complications: Retrobulbar haemorrhage can occur due to penetration of arteries and veins in the orbit. Venous haemorrhage is slow in onset and does not usually threaten vision. Arterial haemorrhages are rapid and can result in proptosis, tight lid, ecchymosis and increased IOP. It can even result in blindness due to central retinal artery occlusion. Firm digital pressure can be applied to stop bleeding. IOP can be reduced with oral acetazolamide and intravenous mannitol. When nothing else is working lateral canthotomy or paracentesis can be performed in an attempt to control pressure.

Globe penetration can occur during retro or peribulbar injection. It can result in retinal or vitreous incarceration in

wound, pre-retinal or sub-retinal bleed, pain, hypotony and sudden loss of vision. Risk factors include pathological myopia, deep set eyes and repeated injections.

Optic nerve damage can occur during retrobulbar injections especially if given in the classic location at the junction of medial 2/3 and lateral 1/3 of inferior orbital rim and in patients with small globe.

Muscle damage can occur due to direct myotoxic effect of anaesthetic agents, physical trauma by needle and pressure induced ischemia/necrosis.

Advantages of Retrobulbar Block Over Peribulbar Block:

1. Lesser quantity of anaesthetic solution is required
2. Less requirement of anaesthetic supplementation
3. Faster onset of action
4. Lesser chance of lid ecchymosis

Advantages of Peribulbar Block Over Retrobulbar Block:

1. Less painful
2. No need of facial block
3. Lesser chance of retrobulbar haemorrhage, optic nerve damage, oculo cardiac reflex and brainstem anaesthesia

NERVE BLOCKS

Squeezing of eyelids can cause a raise IOP and increased vitreous thrust during surgeries. Squeezing occurs due to contraction of orbicularis oculi muscles which are supplied by facial nerve. Facial nerve can be blocked by the following methods-

1. Van Lint's block- Anaesthetic solution is injected at the junction of lines drawn along the inferior and lateral orbital margins. This way only terminal branches of facial nerve supplying the orbicularis oculi are blocked.
2. O' Briens block- Here block is given to the trunk of facial nerve, just anterior to the tragus of ear, near the neck of the mandible.
3. Atkinson's block- Here block is given to the superior branch of facial nerve as it passes along the inferior margin of the zygomatic bone.
4. Nadbath block- The facial nerve is blocked at the stylomastoid foramen before it enters the parotid gland.

5. Spaeth block- Facial nerve trunk is blocked at a site more proximal to the site used in O'Brien's block.

CANNULA BASED INJECTION TECHNIQUES

Subtenons block

It is a simple safe and effective substitute to needle assisted blocks. After instilling topical anaesthesia into the eye, under sterile conditions the conjunctiva and tenon capsule is held in the inferonasal quadrant about 3-4 mm away from the limbus and a small incision is made with the help of scissors to expose sclera. Using a blunt curved cannula mounted over a 5 ml syringe anaesthetic solution is inserted in the sub tenon plane after inserting the cannula and moving it along the curvature of sclera [18]. 2 % lignocaine is the most common anaesthetic solution which is used [19]. Short ciliary nerves are blocked as they pierce the tenon capsule and motor nerves are blocked close to their site of entry into the muscles. There is lesser chance of complications such as globe perforation, optic nerve damage and retrobulbar haemorrhage. However, there can still be significant rise in IOP, conjunctival haemorrhage and conjunctival ballooning which can interfere with certain surgical steps.

Non Akinetic Techniques

Topical Anaesthesia: In the last few years there has been an increase in use of topical anaesthesia for cataract surgery. With development of better fluidics and phaco tips, cataract surgeries have become fast, safe and mostly sutureless. 0.5% Proparacaine and 2-4% lignocaine can be used as topical agents on the day of surgery to anaesthetize the nerves [20]. They are extremely safe and avoid all the needle and cannula associated complications. However, anaesthetic effect is limited to cornea, conjunctiva and anterior sclera only. The iris and ciliary body are not anaesthetized and even slight manipulations can lead to significant discomfort to the patient. Because of the absence of motor block, patient cooperation becomes extremely important when any surgery is performed under topical anaesthesia. Ropivacaine and bupivacaine have also shown efficacy as topical anaesthetic agents [21].

Intracameral Anaesthesia: Topical anaesthesia can be combined with injection of 1% lignocaine solution into the anterior chamber through paracentesis or by side port incision. This provides anaesthetic effect on iris and ciliary body. The

drug should not be allowed to stay in anterior chamber for more than 15 to 30 seconds to avoid retinal toxicity [22].

GENERAL ANAESTHESIA

Indications of surgery under general anaesthesia:

1. Surgical procedure on patients who are unlikely to cooperate in local anaesthesia such as children, mentally retarded, deaf and dumb patients.
2. Extensive operations where local anaesthesia is insufficient.
3. When administration of local anaesthesia is not possible due infected field.
4. Allergy to local anaesthetic agents.
5. Uncontrolled neurological movements involving head [23].
6. Penetrating/perforating eye surgeries.

Adult patients are instructed not to eat or drink anything for eight hours before surgery. For breast feeding infants this duration can be reduced to about 4 hours. This results in an empty stomach and reduces the chance of aspiration during extubation.

First an intravenous line is put. Some relaxing agent can be administered through it before going to operating room. In the operating room a sleep inducing agent is administered and then breathing tube is inserted so that patients breathing can be controlled during anaesthesia. In order to maintain anaesthesia, intravenous or inhalational agent through this tube can be used.

During eye surgery, a deep plane of anaesthesia is maintained in order to avoid coughing, laryngospasm and any movements which can increase IOP. In deep level of anaesthesia eye tends to deviated downwards and vice-versa. In earlier days, endotracheal intubation was the most common method used as it is easy to maintain long duration anaesthesia with it with minimal risk of aspiration. During endotracheal intubation, a non-depolarising muscle relaxant (vecuronium or rocuronium) is administered and titrated according to state of muscle relaxation. With the advent of supraglottic airway devices need for neuromuscular agents have decreased. However, studies have shown that addition of muscle relaxants such as atracurium and rocuronium during general anaesthesia results in better surgical conditions [24]. Short duration procedures can

be done under laryngeal mask airways but there is higher chance of aspiration with it.

General anaesthesia is usually very safe. Many patients experience nausea and vomiting in post anaesthesia period, especially after muscle surgeries. But it is rarely severe enough to warrant any worry. Serious complications are very rare. These include respiratory depression, spasm, hypoxemia, hyper/hypocapnia, aspiration pneumonia, brainstem depression, anaphylactic reaction and death.

Complications also depend upon the agent used for anaesthesia. N₂O should not be used in any case where intraocular gas/air is present or planned to be injected as it can cause rapid expansion of intraocular gas/air and cause dramatic increase in IOP. Most agents used for anaesthesia are associated with a decrease in IOP. Ketamine and succinylcholine are two agents which if used are known to cause an increase in IOP. Ketamine is also known to cause hallucinations and nightmares. Use of succinylcholine is associated with severe muscle pain in post op period and enflurane can cause renal dysfunction [25].

CONCLUSION

A wide variety of anaesthesia techniques are available for surgeons. Each procedure for ophthalmic anaesthesia offers certain benefits, which have to weigh against the risks associated with it. Decision-making takes into account patient profile and ophthalmic procedure while ensuring patient comfort and safety. With advances in medicine, ophthalmic anaesthesia can be considered effective, convenient and safe in most cases.

REFERENCES

1. Markel H. (2011). Über Coca: Sigmund Freud, Carl Koller and Cocaine. *JAMA*. Apr 6. 305: 1360.
2. Katz J, Feldman MA, Bass EB, Lubomski LH, Tielsch JM, et al. (2003). Risks and benefits of anticoagulant and antiplatelet medication use before cataract surgery. *Ophthalmology*. Sep. 110: 1784-1788.
3. Davies BR. (2004). Combined aspirin and clopidogrel in cataract surgical patients: a new risk factor for ocular haemorrhage? *Br J Ophthalmol*. Sep. 88: 1226-1227.
4. Kara-Junior N, Koch CR, Santhiago MR de, Fornari L, Caramelli B. (2018). Anticoagulants and antiplatelet drugs during cataract surgery. *Arq Bras Oftalmol*. 81: 348-353.
5. Gómez-Arnau JI, Yangüela J, González A, Andrés Y, García del Valle S, et al. (2003). Anaesthesia-related diplopia after cataract surgery. *Br J Anaesth*. 90: 189-193.
6. Fanning GL. (2006). Orbital regional anesthesia. *Ophthalmol Clin N Am*. 19: 221-132.
7. Dempsey GA, Barrett PJ, Kirby IJ. (1997). Hyaluronidase and peribulbar block. *Br J Anaesth*. 78: 671-674.
8. Swathi N, Srikanth K, Venipriya S. (2018). Does the addition of hyaluronidase improve the quality of peribulbar anesthesia in cataract surgery? - A randomized double blinded study. *Saudi J Ophthalmol Off J Saudi Ophthalmol Soc*. 32: 204-210.
9. Aksu R, Bicer C, Ozkiris A, Akin A, Bayram A, et al. (2009). Comparison of 0.5% levobupivacaine, 0.5% bupivacaine, and 2% lidocaine for retrobulbar anesthesia in vitreoretinal surgery. *Eur J Ophthalmol*. 19: 280-284.
10. Borazan M, Karalezli A, Akova YA, Algan C, Oto S. (2008). Comparative clinical trial of topical anaesthetic agents for cataract surgery with phacoemulsification: lidocaine 2% drops, levobupivacaine 0.75% drops, and ropivacaine 1% drops. *Eye Lond Engl*. 22: 425-429.
11. Calenda E, Quintyn JC, Bresseur G. (2002). Peribulbar anaesthesia using a combination of lidocaine, bupivacaine and clonidine in vitreoretinal surgery. *Indian J Ophthalmol*. 50: 205-208.
12. Bharti N, Madan R, Kaul HL, Khokhar SK, Mishra S. (2002). Effect of addition of clonidine to local anaesthetic mixture for peribulbar block. *Anaesth Intensive Care*. 30: 438-441.
13. Nehra P, Oza V, Parmar V, Fumakiya P. (2017). Effect of addition of fentanyl and clonidine to local anesthetic solution in peribulbar block. *J Pharmacol Pharmacother*. 8: 3-7.
14. Sinha R, Sharma A, Ray B, Chandiran R, Chandralekha C, et al. (2016). Effect of addition of magnesium to local anesthetics for peribulbar block: A prospective randomized double-blind study. *Saudi J Anaesth*. 10: 64-67.
15. Gadkari SS. (2007). Evaluation of 19 cases of inadvertent globe perforation due to periocular injections. *Indian J Ophthalmol*. 55: 103-107.

16. Lee DS, Kwon NJ. (1988). Shivering following retrobulbar block. *Can J Anaesth J Can Anesth.* 35: 294-296.
17. Gomez RS, Andrade LO, Costa JR. (1997). Brainstem anaesthesia after peribulbar anaesthesia. *Can J Anaesth J Can Anesth.* 44: 732-734.
18. Hansen EA, Mein CE, Mazzoli R. (1990). Ocular anesthesia for cataract surgery: a direct sub-Tenon's approach. *Ophthalmic Surg.* 21: 696-699.
19. McLure HA, Rubin AP. (2005). Review of local anaesthetic agents. *Minerva Anesthesiol.* 71: 59-74.
20. Koch PS. (1999). Efficacy of lidocaine 2% jelly as a topical agent in cataract surgery. *J Cataract Refract Surg.* 25: 632-634.
21. Martini E, Cavallini GM, Campi L, Lugli N, Neri G, et al. (2002). Lidocaine versus ropivacaine for topical anesthesia in cataract surgery(1). *J Cataract Refract Surg.* 28: 1018-1022.
22. Martin RG, Miller JD, Cox CC, Ferrel SC, Raanan MG. (1998). Safety and efficacy of intracameral injections of unpreserved lidocaine to reduce intraocular sensation. *J Cataract Refract Surg.* 24: 961-963.
23. Gupta S, Ganguly A, Shende D, Khokhar S. (2014). Prevalence and indications of general anesthesia for adult cataracts in a tertiary care centre in India. *Indian J Anaesth.* 58: 231-232.
24. Darlong V, Garg R, Pandey R, Khokhar S, Chandrlekha null, et al. (2015). Evaluation of minimal dose of atracurium for cataract surgery in children: A prospective randomized double-blind study. *Saudi J Anaesth.* 9: 283-288.
25. Harris M, Chung F. (2013). Complications of general anesthesia. *Clin Plast Surg.* 40: 503-513.